

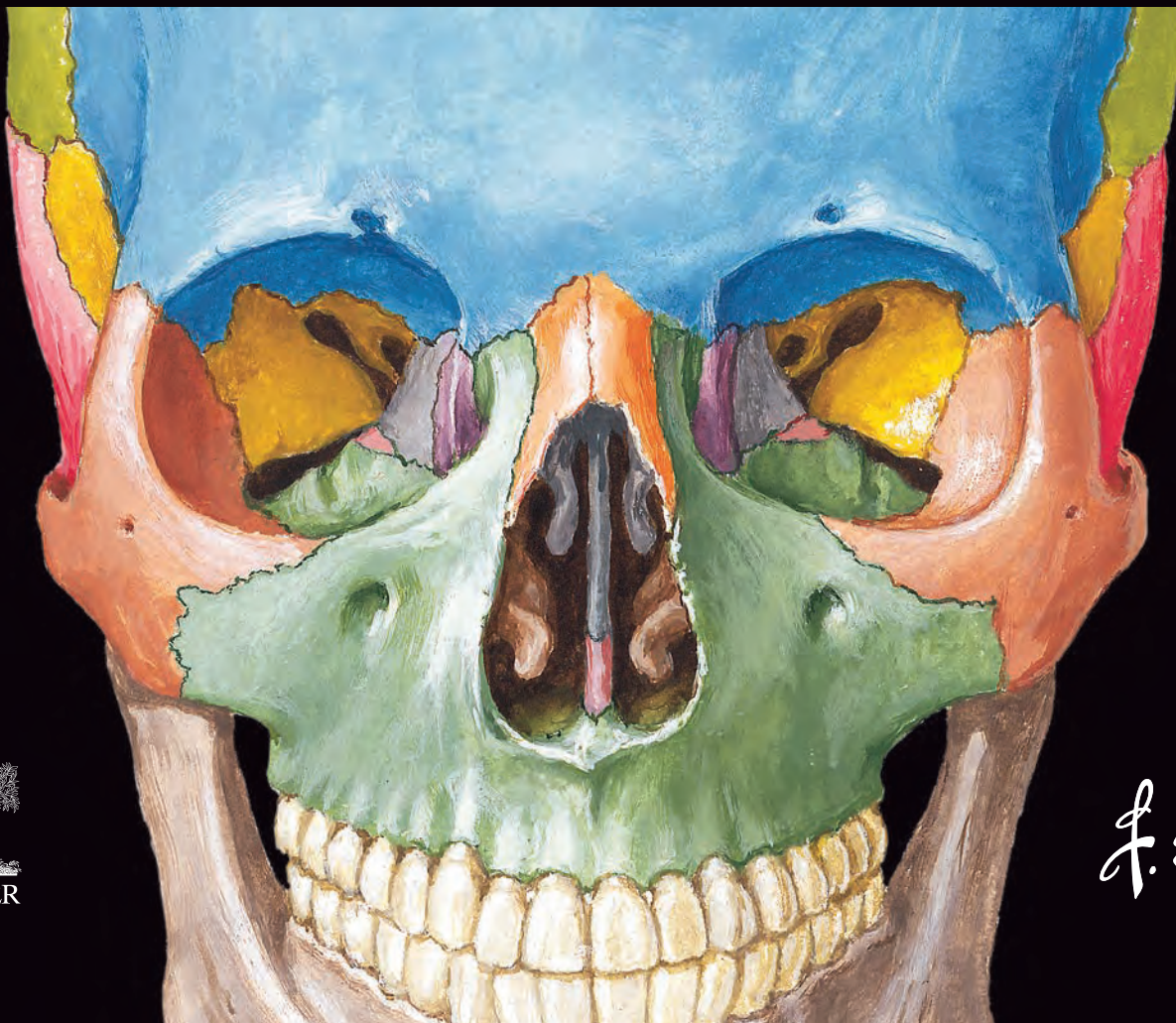EIGHTH EDITION

8

FRANK H. NETTER, MD

NETTER ATLAS
of HUMAN
ANATOMY

Classic Regional Approach



ELSEVIER
1600 John F. Kennedy Blvd.
Ste. 1600
Philadelphia, PA 19103-2899

**ATLAS OF HUMAN ANATOMY: CLASSIC REGIONAL APPROACH,
EIGHTH EDITION**

Standard Edition: 978-0-323-68042-4
Professional Edition: 978-0-323-79373-5
International Edition: 978-0-323-79374-2

Copyright © 2023 by Elsevier Inc.

Previous editions copyrighted 2019, 2014, 2011, 2006, 2003, 1997, 1989

All rights reserved. No part of this publication may be reproduced or transmitted in any form or by any means, electronic or mechanical, including photocopying, recording, or any information storage and retrieval system, without permission in writing from the publisher. Details on how to seek permission, further information about the Publisher's permissions policies and our arrangements with organizations such as the Copyright Clearance Center and the Copyright Licensing Agency can be found at our website: www.elsevier.com/permissions.

This book and the individual contributions contained in it are protected under copyright by the Publisher (other than as may be noted herein).

Permission to use Netter Art figures may be sought through the website NetterImages.com or by emailing Elsevier's Licensing Department at H.Licensing@elsevier.com.

Notices

Knowledge and best practice in this field are constantly changing. As new research and experience broaden our understanding, changes in research methods, professional practices, or medical treatment may become necessary.

Practitioners and researchers must always rely on their own experience and knowledge in evaluating and using any information, methods, compounds, or experiments described herein. In using such information or methods they should be mindful of their own safety and the safety of others, including parties for whom they have a professional responsibility.

With respect to any drug or pharmaceutical products identified, readers are advised to check the most current information provided (i) on procedures featured or (ii) by the manufacturer of each product to be administered, to verify the recommended dose or formula, the method and duration of administration, and contraindications. It is the responsibility of practitioners, relying on their own experience and knowledge of their patients, to make diagnoses, to determine dosages and the best treatment for each individual patient, and to take all appropriate safety precautions.

To the fullest extent of the law, neither the Publisher nor the authors, contributors, or editors, assume any liability for any injury and/or damage to persons or property as a matter of products liability, negligence or otherwise, or from any use or operation of any methods, products, instructions, or ideas contained in the material herein.

International Standard Book Number: 978-0-323-68042-4

Publisher: Elyse O'Grady
Senior Content Strategist: Marybeth Thiel
Publishing Services Manager: Catherine Jackson
Senior Project Manager/Specialist: Carrie Stetz
Book Design: Renee Duenow

Printed in China

9 8 7 6 5 4 3 2 1



Working together
to grow libraries in
developing countries

www.elsevier.com • www.bookaid.org

CONSULTING EDITORS

Chief Contributing Illustrator and Art Lead Editor

Carlos A.G. Machado, MD

Terminology Content Lead Editors

Paul E. Neumann, MD

Professor, Department of Medical Neuroscience
Faculty of Medicine
Dalhousie University
Halifax, Nova Scotia
Canada

R. Shane Tubbs, MS, PA-C, PhD

Professor of Neurosurgery, Neurology, Surgery, and Structural and Cellular Biology
Director of Surgical Anatomy, Tulane University School of Medicine
Program Director of Anatomical Research, Clinical Neuroscience Research Center, Center for Clinical Neurosciences
Department of Neurosurgery, Tulane University School of Medicine, New Orleans, Louisiana
Department of Neurology, Tulane University School of Medicine, New Orleans, Louisiana
Department of Structural and Cellular Biology, Tulane University School of Medicine, New Orleans, Louisiana
Professor, Department of Neurosurgery, and Ochsner Neuroscience Institute, Ochsner Health System, New Orleans, Louisiana
Professor of Anatomy, Department of Anatomical Sciences, St. George's University, Grenada
Honorary Professor, University of Queensland, Brisbane, Australia
Faculty, National Skull Base Center of California, Thousand Oaks, California

Electronic Content Lead Editors

Brion Benninger, MD, MBChB, MSc

Professor of Medical Innovation, Technology, & Research
Director, Ultrasound
Professor of Clinical Anatomy
Executive Director, Medical Anatomy Center
Department of Medical Anatomical Sciences
Faculty, COMP and COMP-Northwest
Faculty College of Dentistry, Western University of Health Sciences, Lebanon, Oregon and Pomona, California
Faculty, Sports Medicine, Orthopaedic & General Surgery Residencies
Samaritan Health Services, Corvallis, Oregon
Faculty, Surgery, Orthopedics & Rehabilitation, and Oral Maxillofacial Surgery
Oregon Health & Science University, Portland, Oregon
Visiting Professor of Medical Innovation and Clinical Anatomy, School of Basic Medicine, Peking Union Medical College, Beijing, China
Professor of Medical Innovation and Clinical Anatomy Post Graduate Diploma Surgical Anatomy, Otago University, Dunedin, New Zealand

Todd M. Hoagland, PhD

Clinical Professor of Biomedical Sciences and Occupational Therapy
Marquette University College of Health Sciences
Milwaukee, Wisconsin

Educational Content Lead Editors

Jennifer K. Brueckner-Collins, PhD

Distinguished Teaching Professor
Vice Chair for Educational Programs
Department of Anatomical Sciences and Neurobiology
University of Louisville School of Medicine
Louisville, Kentucky

Martha Johnson Gdowski, PhD

Associate Professor and Associate Chair of Medical Education,
Department of Neuroscience
University of Rochester School of Medicine and Dentistry
Rochester, NY

Virginia T. Lyons, PhD

Associate Professor of Medical Education
Associate Dean for Preclinical Education
Geisel School of Medicine at Dartmouth
Hanover, New Hampshire

Peter J. Ward, PhD

Professor
Department of Biomedical Sciences
West Virginia School of Osteopathic Medicine
Lewisburg, West Virginia

Emeritus Editor

John T. Hansen, PhD

Professor Emeritus of Neuroscience and former Schmitt Chair of Neurobiology and Anatomy and Associate Dean for Admissions University of Rochester Medical Center
Rochester, New York

EDITORS OF PREVIOUS EDITIONS

First Edition

Sharon Colacino, PhD

Second Edition

Arthur F. Dalley II, PhD

Third Edition

Carlos A.G. Machado, MD

John T. Hansen, PhD

Fourth Edition

Carlos A.G. Machado, MD

John T. Hansen, PhD

Jennifer K. Brueckner, PhD

Stephen W. Carmichael, PhD, DSc

Thomas R. Gest, PhD

Noelle A. Granger, PhD

Anil H. Waljii, MD, PhD

Fifth Edition

Carlos A.G. Machado, MD

John T. Hansen, PhD

Brion Benninger, MD, MS

Jennifer K. Brueckner, PhD

Stephen W. Carmichael, PhD, DSc

Noelle A. Granger, PhD

R. Shane Tubbs, MS, PA-C, PhD

Sixth Edition

Carlos A.G. Machado, MD

John T. Hansen, PhD

Brion Benninger, MD, MS

Jennifer Brueckner-Collins, PhD

Todd M. Hoagland, PhD

R. Shane Tubbs, MS, PA-C, PhD

Seventh Edition

Carlos A.G. Machado, MD

John T. Hansen, PhD

Brion Benninger, MD, MS

Jennifer Brueckner-Collins, PhD

Todd M. Hoagland, PhD

R. Shane Tubbs, MS, PA-C, PhD

OTHER CONTRIBUTING ILLUSTRATORS

Rob Duckwall, MA (DragonFly Media Group)

Kristen Wienandt Marzejon, MS, MFA

Tiffany S. DaVanzo, MA, CMI

James A. Perkins, MS, MFA

INTERNATIONAL ADVISORY BOARD

Nihal Apaydin, MD, PhD

Professor of Anatomy
Faculty of Medicine, Department of
Anatomy
Ankara University;
Chief, Department of Multidisciplinary
Neuroscience
Institute of Health Sciences
Ankara, Turkey

Hassan Amiralli, MD, MS, FUICC

Professor and Chair
Department of Anatomy
American University of Antigua College
of Medicine
Antigua, West Indies;
Former Professor of Surgery
Muhimbili University of Health Sciences
Daressalaam, Tanzania

**Belinda R. Beck, BHMS(Ed),
MS, PhD**

Professor of Anatomy and Exercise
Science
Director, Bone Densitometry Research
Laboratory
Griffith University, Gold Coast Campus
Queensland, Australia

Jonathan Campbell, MD, FAAOS

Assistant Professor of Orthopaedic
Surgery
Division of Sports Medicine
Medical College of Wisconsin
Milwaukee, Wisconsin

Francisco J. Caycedo, MD, FAAOS

St. Vincent's Hospital
Birmingham, Alabama

**Thazhumpal Chacko Mathew, MSc, PhD,
FRCPath**

Professor
Faculty of Allied Health Sciences
Health Sciences Centre
Kuwait University
Kuwait City, Kuwait

Eduardo Cotecchia Ribeiro, MS, PhD

Associate Professor of Descriptive and
Topographic Anatomy
School of Medicine
Federal University of São Paulo
São Paulo, Brazil

William E. Cullinan, PhD

Professor and Dean
College for Health Sciences
Marquette University
Milwaukee, Wisconsin

Elisabeth Eppler, MD

University Lecturer
Institute of Anatomy
University of Berne
Berne, Switzerland

Christopher Kelly, MD, MS

North Carolina Heart and Vascular
Raleigh, North Carolina

Michelle D. Lazarus, PhD

Director, Centre for Human Anatomy
Education
Monash Centre for Scholarship in Health
Education (MCSHE) Curriculum
Integration Network Lead
Monash Education Academy Fellow
Monash University
Clayton, Victoria, Australia

Robert G. Louis, MD, FAANS

Empower360 Endowed Chair for
Skull Base and Minimally Invasive
Neurosurgery
Chair, Division of Neurosurgery
Pickup Family Neurosciences Institute
Hoag Memorial Hospital
Newport Beach, California

Chao Ma, MD

Department of Human Anatomy,
Histology & Embryology
Peking Union Medical College
Beijing, China

Diego Pineda Martínez, MD, PhD

Chief, Department of Innovation in
Human Biological Material
Professor of Anatomy
Faculty of Medicine of the National
Autonomous University of Mexico
President, Mexican Society of Anatomy
Mexico City, Mexico

William J. Swartz, PhD

Emeritus Professor of Cell Biology and
Anatomy
Louisiana State University Health
Sciences Center
New Orleans, Louisiana

Kimberly S. Topp, PT, PhD, FAAA

Professor and Chair Emeritus
Department of Physical Therapy and
Rehabilitation Science
School of Medicine
University of California San Francisco
San Francisco, California

Ivan Varga, PhD

Professor of Anatomy, Histology, and
Embryology
Faculty of Medicine
Comenius University
Bratislava, Slovak Republic

Robert J. Ward, MD, CCD, DABR

Chief Executive Officer
Sullivan's Island Imaging, LLC
Sullivan's Island, South Carolina;
Professor of Radiology
Saint Georges University
Grenada, West Indies

Alexandra L. Webb, BSc, MChiro, PhD

Associate Professor
Deputy Director, Medical School
College of Health and Medicine
Australian National University
Canberra, ACT, Australia

PREFACE

The illustrations comprising the *Netter Atlas of Human Anatomy* were painted by physician-artists, Frank H. Netter, MD, and Carlos Machado, MD. Dr. Netter was a surgeon and Dr. Machado is a cardiologist. Their clinical insights and perspectives have informed their approaches to these works of art. The collective expertise of the anatomists, educators, and clinicians guiding the selection, arrangement, labeling, and creation of the illustrations ensures the accuracy, relevancy, and educational power of this outstanding collection.

You have a copy of the **regionally organized** 8th edition with English language terminology. This is the traditional organization and presentation that has been used since the first edition. Also available is a Latin terminology option that is also regionally organized, as well as an option with English terminology organized by body system. In all cases, the same beautiful and instructive Art Plates and Table information are included.

New to this Edition

New Art

More than 20 new illustrations have been added and over 30 art modifications have been made throughout this edition. Highlights include new views of the temporal and infratemporal fossa, pelvic fascia, nasal cavity and paranasal sinuses, plus multiple new perspectives of the heart, a cross-section of the foot, enhanced surface anatomy plates, and overviews of many body systems. In these pages you will find the most robust illustrated coverage to date for modern clinical anatomy courses.

Terminology and Label Updates

This 8th edition incorporates terms of the *Terminologia Anatomica* (2nd edition), as published by the Federative International Programme on Anatomical Terminology in 2019 (<https://fipat.library.dal.ca/ta2>) and adopted by the International Federation of Associations of Anatomy in 2020. A fully searchable database of the updated *Terminologia Anatomica* can be accessed at <https://ta2viewer.openanatomy.org>. Common clinical eponyms and former terminologies are selectively included, parenthetically, for clarity. In addition, a strong effort has been made to reduce label text on the page while maximizing label information through the use of abbreviations (muscle/s = m/mm.; artery/ies = a./aa.; vein/s = v./vv.; and nerve/s = n./nn.) and focusing on the labels most relevant to the subject of each Plate.


Nerve Tables

The muscle tables and clinical tables of previous editions have been so positively received that new tables have been added to cover four major nerve groups: cranial nerves and the nerves of the cervical, brachial, and lumbosacral plexuses.

Future of the Netter Anatomy Atlas

As the Netter Atlas continues to evolve to meet the needs of students, educators, and clinicians, we welcome suggestions! Please use the following form to provide your feedback:

<https://tinyurl.com/NetterAtlas8>



To my dear wife, Vera

PREFACE TO THE FIRST EDITION

I have often said that my career as a medical artist for almost 50 years has been a sort of “command performance” in the sense that it has grown in response to the desires and requests of the medical profession. Over these many years, I have produced almost 4,000 illustrations, mostly for *The CIBA (now Netter) Collection of Medical Illustrations* but also for *Clinical Symposia*. These pictures have been concerned with the varied subdivisions of medical knowledge such as gross anatomy, histology, embryology, physiology, pathology, diagnostic modalities, surgical and therapeutic techniques, and clinical manifestations of a multitude of diseases. As the years went by, however, there were more and more requests from physicians and students for me to produce an atlas purely of gross anatomy. Thus, this atlas has come about, not through any inspiration on my part but rather, like most of my previous works, as a fulfillment of the desires of the medical profession.

It involved going back over all the illustrations I had made over so many years, selecting those pertinent to gross anatomy, classifying them and organizing them by system and region, adapting them to page size and space, and arranging them in logical sequence. Anatomy of course does not change, but our understanding of anatomy and its clinical significance does change, as do anatomical terminology and nomenclature. This therefore required much updating of many of the older pictures and

even revision of a number of them in order to make them more pertinent to today’s ever-expanding scope of medical and surgical practice. In addition, I found that there were gaps in the portrayal of medical knowledge as pictorialized in the illustrations I had previously done, and this necessitated my making a number of new pictures that are included in this volume.

In creating an atlas such as this, it is important to achieve a happy medium between complexity and simplification. If the pictures are too complex, they may be difficult and confusing to read; if oversimplified, they may not be adequately definitive or may even be misleading. I have therefore striven for a middle course of realism without the clutter of confusing minutiae. I hope that the students and members of the medical and allied professions will find the illustrations readily understandable, yet instructive and useful.

At one point, the publisher and I thought it might be nice to include a foreword by a truly outstanding and renowned anatomist, but there are so many in that category that we could not make a choice. We did think of men like Vesalius, Leonardo da Vinci, William Hunter, and Henry Gray, who of course are unfortunately unavailable, but I do wonder what their comments might have been about this atlas.

Frank H. Netter, MD
(1906–1991)

FRANK H. NETTER, MD

Frank H. Netter was born in New York City in 1906. He studied art at the Art Students League and the National Academy of Design before entering medical school at New York University, where he received his Doctor of Medicine degree in 1931. During his student years, Dr. Netter’s notebook sketches attracted the attention of the medical faculty and other physicians, allowing him to augment his income by illustrating articles and textbooks. He continued illustrating as a sideline after establishing a surgical practice in 1933, but he ultimately opted to give up his practice in favor of a full-time commitment to art. After service in the United States Army during World War II, Dr. Netter began his long collaboration with the CIBA Pharmaceutical Company (now Novartis Pharmaceuticals). This 45-year partnership resulted in the production of the extraordinary collection of medical art so familiar to physicians and other medical professionals worldwide.

Icon Learning Systems acquired the Netter Collection in July 2000 and continued to update Dr. Netter’s original paintings and to add newly commissioned paintings by artists trained in the style of Dr. Netter. In 2005, Elsevier Inc. purchased the Netter Collection and all publications from Icon Learning Systems. There are now over

50 publications featuring the art of Dr. Netter available through Elsevier Inc.

Dr. Netter’s works are among the finest examples of the use of illustration in the teaching of medical concepts. The 13-book *Netter Collection of Medical Illustrations*, which includes the greater part of the more than 20,000 paintings created by Dr. Netter, became and remains one of the most famous medical works ever published. *The Netter Atlas of Human Anatomy*, first published in 1989, presents the anatomic paintings from the Netter Collection. Now translated into 16 languages, it is the anatomy atlas of choice among medical and health professions students the world over.

The Netter illustrations are appreciated not only for their aesthetic qualities, but, more importantly, for their intellectual content. As Dr. Netter wrote in 1949 “clarification of a subject is the aim and goal of illustration. No matter how beautifully painted, how delicately and subtly rendered a subject may be, it is of little value as a *medical illustration* if it does not serve to make clear some medical point.” Dr. Netter’s planning, conception, point of view, and approach are what inform his paintings and what make them so intellectually valuable.

Frank H. Netter, MD, physician and artist, died in 1991.

ABOUT THE EDITORS

Carlos A.G. Machado, MD was chosen by Novartis to be Dr. Netter's successor. He continues to be the main artist who contributes to the Netter collection of medical illustrations.

Self-taught in medical illustration, cardiologist Carlos Machado has contributed meticulous updates to some of Dr. Netter's original plates and has created many paintings of his own in the style of Netter as an extension of the Netter collection. Dr. Machado's photorealistic expertise and his keen insight into the physician/patient relationship inform his vivid and unforgettable visual style. His dedication to researching each topic and subject he paints places him among the premier medical illustrators at work today.

Learn more about his background and see more of his art at: <https://netterimages.com/artist-carlos-a-g-machado.html>

Paul E. Neumann, MD was clinically trained in anatomical pathology and neuropathology. Most of his research publications have been in mouse neurogenetics and molecular human genetics. In the past several years, he has concentrated on the anatomical sciences, and has frequently written about anatomical terminology and anatomical ontology in the journal *Clinical Anatomy*. As an officer of the Federative International Programme for Anatomical Terminology (FIPAT), he participated in the production of *Terminologia Anatomica* (2nd edition), *Terminologia Embryologica* (2nd edition), and *Terminologia Neuroanatomica*. In addition to serving as the lead Latin editor of the 8th edition of *Netter's Atlas*, he was a contributor to the 33rd edition of *Dorland's Illustrated Medical Dictionary*.

R. Shane Tubbs, MS, PA-C, PhD is a native of Birmingham, Alabama and a clinical anatomist. His research interests are centered around clinical/surgical problems that are identified and solved with anatomical studies. This investigative paradigm in anatomy as resulted in over 1,700 peer reviewed publications. Dr. Tubbs' laboratory has made novel discoveries in human anatomy including a new nerve to the skin of the lower eyelid, a new space of the face, a new venous sinus over the spinal cord, new connections between the parts of the sciatic nerve, new ligaments of the neck, a previously undescribed cutaneous branch of the inferior gluteal nerve, and an etiology for postoperative C5 nerve palsies. Moreover, many anatomical feasibility studies from Dr. Tubbs' laboratory have gone on to be used by surgeons from around the world and have thus resulted in new surgical/clinical procedures such as treating hydrocephalus by shunting cerebrospinal fluid into various bones, restoration of upper limb function in paralyzed patients with neurotization procedures using the contralateral spinal accessory nerve, and harvesting of clavicle for anterior cervical discectomy and fusion procedures in patients with cervical instability or degenerative spine disease.

Dr. Tubbs sits on the editorial board of over 15 anatomical journals and has reviewed for over 150 scientific journals. He has been a visiting professor to major institutions in the United States and worldwide. Dr. Tubbs has authored over 40 books and over 75 book chapters. His published books by Elsevier include *Gray's Anatomy Review*, *Gray's Clinical Photographic Dissector of the Human Body*, *Netter's Introduction to Clinical Procedures*, and *Nerves and Nerve Injuries* volumes I and II. He is an editor for the 41st and 42nd editions of the over 150-year-old *Gray's Anatomy*, the 5th through 8th editions of *Netter's Atlas of Anatomy*, and is the editor-in-chief of the journal *Clinical Anatomy*. He is the Chair of the Federative International Programme on Anatomical Terminologies (FIPAT).

Jennifer K. Brueckner-Collins, PhD is a proud Kentucky native. She pursued her undergraduate and graduate training at the University of Kentucky. During her second year of graduate school there, she realized that her professional calling was not basic science research in skeletal muscle biology, but was instead helping medical students master the anatomical sciences. She discovered this during a required teaching assistantship in medical histology, where working with students at the 10-headed microscope changed her career path.

The next semester of graduate school, she assisted in teaching dissection-based gross anatomy, although she had taken anatomy when the lab component was prosection based. After teaching in the first lab, she knew that she needed to learn anatomy more thoroughly through dissection on her own, so she dissected one to two labs ahead of the students that semester; that was when she really learned anatomy and was inspired to teach this discipline as a profession. All of this occurred in the early 1990s, when pursuing a teaching career was frowned upon by many; it was thought that you only pursued this track if you were unsuccessful in research. She taught anatomy part-time during the rest of her graduate training, on her own time, to gain requisite experience to ultimately secure a faculty position.

Dr. Brueckner-Collins spent 10 years at the University of Kentucky as a full-time faculty member teaching dissection-based gross anatomy to medical, dental, and allied health students. Then, after meeting the love of her life, she moved to the University of Louisville and has taught medical and dental students there for more than a decade. Over 20 years of teaching full time at two medical schools in the state, her teaching efforts have been recognized through receipt of the highest teaching honor at each medical school in the state, the Provost's Teaching Award at University of Kentucky, and the Distinguished Teaching Professorship at University of Louisville.

Martha Johnson Gdowski, PhD earned her BS in Biology cum laude from Gannon University in 1990, followed by a PhD in Anatomy from the Pennsylvania State University College of Medicine in 1995. She completed postdoctoral

fellowships at the Cleveland Clinic and Northwestern University School of Medicine prior to accepting a faculty position in the Department of Neuroscience at the University of Rochester School of Medicine and Dentistry in 2001. Previous research interests include the development of an adult model of hydrocephalus, sensorimotor integration in the basal ganglia, and sensorimotor integration in normal and pathological aging.

Her passion throughout her career has been in her service as an educator. Her teaching has encompassed a variety of learning formats, including didactic lecture, laboratory, journal club, and problem-based learning. She has taught for four academic institutions in different capacities (The Pennsylvania State University School of Medicine, Northwestern University School of Medicine, Ithaca College, and The University of Rochester School of Medicine and Dentistry). She has taught in the following curricula: Undergraduate and Graduate Neuroscience, Graduate Neuroanatomy, Graduate Human Anatomy and Physiology for Physical Therapists, Undergraduate Medical Human Anatomy and Histology, and Undergraduate and Graduate Human Anatomy. These experiences have provided an opportunity to instruct students that vary in age, life experience, race, ethnicity, and economic background, revealing how diversity in student populations enriches learning environments in ways that benefit everyone. She has been honored to be the recipient of numerous awards for her teaching and mentoring of students during their undergraduate medical education. Martha enjoys gardening, hiking, and swimming with her husband, Greg Gdowski, PhD, and their dogs, Sophie and Ivy.

Virginia T. Lyons, PhD is an Associate Professor of Medical Education and the Associate Dean for Preclinical Education at the Geisel School of Medicine at Dartmouth. She received her BS in Biology from Rochester Institute of Technology and her PhD in Cell Biology and Anatomy from the University of North Carolina at Chapel Hill. Dr. Lyons has devoted her career to education in the anatomical sciences, teaching gross anatomy, histology, embryology, and neuroanatomy to medical students and other health professions students. She has led courses and curricula in human gross anatomy and embryology for more than 20 years and is a strong advocate for incorporating engaged pedagogies into preclinical medical education. Dr. Lyons has been recognized with numerous awards for teaching and mentoring students and was elected to the Dartmouth chapter of the Alpha Omega Alpha Honor Medical Society. She is the author of *Netter's Essential Systems-Based Anatomy* and co-author of the Human Anatomy Learning Modules website accessed by students worldwide. Dr. Lyons also serves as the Discipline Editor for Anatomy on the Aquifer Sciences Curriculum Editorial Board, working to integrate anatomical concepts into virtual patient cases that are used in multiple settings including clerkships and residency training.

Peter J. Ward, PhD grew up in Casper, Wyoming, graduating from Kelly Walsh High School and then attending Carnegie Mellon University in Pittsburgh, Pennsylvania.

He began graduate school at Purdue University, where he first encountered gross anatomy, histology, embryology, and neuroanatomy. Having found a course of study that engrossed him, he helped teach those courses in the veterinary and medical programs at Purdue. Dr. Ward completed a PhD program in anatomy education and, in 2005, he joined the faculty at the West Virginia School of Osteopathic Medicine (WVSOM) in Lewisburg, West Virginia. There he has taught gross anatomy, embryology, neuroscience, histology, and the history of medicine. Dr. Ward has received numerous teaching awards, including the WVSOM Golden Key Award, the Basmajian Award from the American Association of Anatomists, and has been a two-time finalist in the West Virginia Merit Foundation's Professor of the Year selection. Dr. Ward has also been director of the WVSOM plastination facility, coordinator of the anatomy graduate teaching assistants, chair of the curriculum committee, chair of the faculty council, creator and director of a clinical anatomy elective course, and host of many anatomy-centered events between WVSOM and two Japanese Colleges of Osteopathy. Dr. Ward has also served as council member and association secretary for the American Association of Clinical Anatomists. In conjunction with Bone Clones, Inc., Dr. Ward has produced tactile models that mimic the feel of anatomical structures when intact and when ruptured during the physical examination. He created the YouTube channel Clinical Anatomy Explained! and continues to pursue interesting ways to present the anatomical sciences to the public. Dr. Ward was the Senior Associate Editor for the three volumes of *The Netter Collection: The Digestive System*, 2nd Edition, a contributor to *Gray's Anatomy*, 42nd Edition, and is author of *Netter's Integrated Musculoskeletal System: Clinical Anatomy Explained*.

Brion Benninger, MD, MBChB, MSc currently teaches surgical, imaging, and dynamic anatomy to medical students and residents in several countries (United States, New Zealand, China, Japan, Korea, Taiwan, The Caribbean, Mexico). He develops, invents, and assesses ultrasound probes, medical equipment, simulations, and software while identifying dynamic anatomy. He enjoys mixing educational techniques integrating macro imaging and surgical anatomy. Dr. Benninger developed the teaching theory of anatomy deconstruction/reconstruction and was the first to combine ultrasound with Google Glass during physical examination, coining the term "triple feedback examination." An early user of ultrasound, he continues to develop eFAST teaching and training techniques, has developed and shares a patent on a novel ultrasound finger probe, and is currently developing a new revolutionary ultrasound probe for breast screening. He is a reviewer for several ultrasound, clinical anatomy, surgical, and radiology journals and edits and writes medical textbooks. His research interests integrate clinical anatomy with conventional and emerging technologies to improve training techniques in situ and simulation. Dr. Benninger pioneered and coined the term "dynamic anatomy,"

developed a technique to deliver novel contrast medium to humans, and was the first to reveal vessels and nerves not previously seen using CT and MRI imaging. He has mentored more than 200 students on over 350 research projects presented at national and international conferences and has received numerous awards for projects related to emergency procedures, ultrasound, sports medicine, clinical anatomy, medical simulation, reverse translational research, medical education, and technology. He is proud to have received medical teaching awards from several countries and institutions, including being the first recipient in more than 25 years to receive the Commendation Medal Award from the Commission of Osteopathic Accreditation for innovative clinical anatomy teaching that he designed and facilitated in Lebanon, Oregon. Dr. Benninger has received sports medicine accolades from Sir Roger Bannister regarding his medical invention on shoulder proprioception. He is also Executive Director of the Medical Anatomy Center and collaborates with colleagues globally from surgical and nonsurgical specialties. He is also an invited course speaker for surgical anatomy in New Zealand. Dr. Benninger collects medical history books, loves mountains and sports, and is an anonymous restaurant critic. British mentors directly responsible for his training include Prof. Peter Bell (surgery), Prof. Sir Alec Jeffreys (genetic fingerprinting), Profs. David deBono and Tony Gershlick (cardiology), Prof. Roger Greenhalgh (vascular surgery), Profs. Chris Colton, John Webb, and Angus Wallace (orthopaedics), Prof. Harold Ellis CBE (surgery and clinical anatomy), and Prof. Susan Standing (Guys Hospital/Kings College).

Todd M. Hoagland, PhD is Clinical Professor of Biomedical Sciences and Occupational Therapy at Marquette University in the College of Health Sciences. Previously he was Professor of Anatomy at the Medical College of Wisconsin (MCW). Prior to MCW, Dr. Hoagland was at

Boston University School of Medicine (BUSM) and he still holds an adjunct faculty position at Boston University Goldman School of Dental Medicine. Dr. Hoagland is a passionate teacher and is dedicated to helping students achieve their goals. He believes in being a strong steward of the anatomical sciences, which involves teaching it to students while contemporaneously developing resources to improve the transfer of knowledge and preparing the next generation to be even better teachers. While at BUSM, Dr. Hoagland was a leader for the Carnegie Initiative on the Doctorate in Neuroscience and helped develop the Vesalius Program (teacher training) for graduate students. The program ensures that graduate students learn about effective teaching, receive authentic experiences in the classroom, and understand how to share what they learn via scholarship.

Dr. Hoagland's dedication to health professions education has been richly rewarded by numerous teaching awards from the University of Notre Dame, BUSM, and MCW. Dr. Hoagland received the Award for Outstanding Ethical Leadership in 2009, was inducted into the Alpha Omega Alpha Honor Medical Society in 2010, received the American Association of Anatomists Basmajian Award in 2012, and was inducted into the Society of Teaching Scholars in 2012 and was their director from 2016–2020.

Dr. Hoagland's scholarly activity centers on (1) evaluating content and instructional/learning methodology in Clinical Human Anatomy and Neuroanatomy courses, especially as relevant to clinical practice, (2) translating basic anatomical science research findings into clinically meaningful information, and (3) evaluating professionalism in students to enhance their self-awareness and improve patient care outcomes. Dr. Hoagland is also consulting editor for *Netter's Atlas of Human Anatomy*, co-author for the digital anatomy textbook *AnatomyOne*, and lead author for *Clinical Human Anatomy Dissection Guide*.

ACKNOWLEDGMENTS

Carlos A. G. Machado, MD

With the completion of this 8th edition, I celebrate 27 years contributing to the Netter brand of educational products, 25 years of which have been dedicated to the update—seven editions—of this highly prestigious, from birth, *Atlas of Human Anatomy*. For these 25 years I have had the privilege and honor of working with some of the most knowledgeable anatomists, educators, and consulting editors—my treasured friends—from whom I have learned considerably.

For the last 16 years it has also been a great privilege to be part of the Elsevier team and be under the skillful coordination and orientation of Marybeth Thiel, Elsevier's Senior Content Development Specialist, and Elyse O'Grady, Executive Content Strategist. I thank both for their friendship, support, sensibility, and very dedicated work.

Once more I thank my wife Adriana and my daughter Beatriz for all their love and encouragement, and for patiently steering me back on track when I get lost in philosophical divagations about turning scientific research into artistic inspiration—and vice-versa!

It is impossible to put in words how thankful I am to my much-loved parents, Carlos and Neide, for their importance in my education and in the formation of my moral and ethical values.

I am eternally grateful to the body donors for their inestimable contribution to the correct understanding of human anatomy; to the students, teachers, health professionals, colleagues, educational institutions, and friends who have, anonymously or not, directly or indirectly, been an enormous source of motivation and invaluable scientific references, constructive comments, and relevant suggestions.

My last thanks, but far from being the least, go to my teachers Eugênio Cavalcante, Mário Fortes, and Paulo Carneiro, for their inspiring teachings on the practical application of the knowledge of anatomy.

Paul E. Neumann, MD

It has been a privilege to work on the English and Latin editions of *Netter's Atlas of Human Anatomy*. I thank the staff at Elsevier (especially Elyse O'Grady, Marybeth Thiel and Carrie Stetz), Dr. Carlos Machado, and the other editors for their efforts to produce a new, improved edition. I am also grateful to my wife, Sandra Powell, and my daughter, Eve, for their support of my academic work.

R. Shane Tubbs, MS, PA-C, PhD

I thank Elyse O'Grady and Marybeth Thiel for their dedication and hard work on this edition. As always, I thank my wife, Susan, and son, Isaiah, for their patience with me on such projects. Additionally, I thank Drs. George and Frank Salter who inspired and encouraged me along my path to anatomy.

Jennifer K. Brueckner-Collins, PhD

Reba McEntire once said "To succeed in life, you need three things: a wishbone, a backbone and a funny bone."

My work with the *Netter Atlas* and the people associated with it over the past 15 years has played an instrumental role in helping me develop and sustain these three metaphorical bones in my professional and personal life.

I am forever grateful to John Hansen, who believed in my ability to serve as an editor starting with the 4th edition.

I extend my sincere thanks to Marybeth Thiel and Elyse O'Grady for not only being the finest of colleagues, but part of my professional family as well. Thanks to you both for your professionalism, support, patience, and collegiality.

To Carlos Machado, you continue to amaze me and inspire me with your special gift of bringing anatomy to life through your art.

For this edition, I also count in my blessings, the ability to work closely with the talented team of educational leaders, including Martha Gdowski, Virginia Lyons, and Peter Ward. It is humbling to work with such brilliant and dedicated teachers as we collectively assembled the systems-based *Netter Atlas* concept.

Finally, I dedicate my work on this edition with unconditional and infinite love to Kurt, Lincoln, my Dad in Heaven, as well as my dog boys, Bingo and Biscuit.

Martha Johnson Gdowski, PhD

I am grateful for the honor to work with the team of editors that Elsevier has selected for the preparation of this 8th edition; they are exceptional in their knowledge, passion as educators, and collegiality. I especially would like to thank Elyse O'Grady and Marybeth Thiel, who have been outstanding in their expertise, patience, and guidance. I am grateful to John T. Hansen, PhD, for his guidance, mentorship, and friendship as a colleague at the University of Rochester and for giving me the opportunity to participate in this work. He continues to be an outstanding role model who has shaped my career as an anatomical sciences educator. Special thanks to Carlos Machado for his gift for making challenging anatomical dissections and difficult concepts accessible to students of anatomy through his artistry, research of the details, and thoughtful discussions. I am indebted to the selfless individuals who have gifted their bodies for anatomical study, the students of anatomy, and my colleagues at the University of Rochester, all of whom motivate me to work to be the best educator I can be. I am most grateful for my loving husband and best friend, Greg, who is my greatest source of support and inspiration.

Virginia T. Lyons, PhD

It has been a joy to work with members of the editorial team on the iconic *Atlas of Human Anatomy* by Frank Netter. I would like to thank Elyse O'Grady and Marybeth Thiel for their expert guidance and ability to nourish the creative process while also keeping us focused (otherwise we would have reveled in debating anatomy minutiae for hours!). I am amazed by the talent of Carlos Machado, who is able to transform our ideas into beautiful, detailed illustrations that simplify concepts for students. I appreciate the patience and support of my husband, Patrick, and my

children, Sean and Nora, who keep me sane when things get busy. Finally, I am grateful for the opportunity to teach and learn from the outstanding medical students at the Geisel School of Medicine at Dartmouth. I am fulfilled by their energy, curiosity, and love of learning.

Peter J. Ward, PhD

It is a thrill and honor to contribute to the 8th edition of *Netter's Atlas of Human Anatomy*. It still amazes me that I am helping to showcase the incomparable illustrations of Frank Netter and Carlos Machado. I hope that this atlas continues to bring these works of medical art to a new generation of students as they begin investigating the awesome enigma of the human body. Thanks to all the amazing contributors and to the hardworking team at Elsevier, especially Marybeth Thiel and Elyse O'Grady, for keeping all of us moving forward. Thank you especially to Todd Hoagland for recommending me to the team. I have immense gratitude to James Walker and Kevin Hannon, who introduced me to the world of anatomy. They both seamlessly combined high expectations for their students along with enthusiastic teaching that made the topic fascinating and rewarding. Great thanks to my parents, Robert and Lucinda Ward, for their lifelong support of my education and for the many formative museum trips to stare at dinosaur bones. Sarah, Archer, and Dashiell, you are all the reason I work hard and try to make the world a slightly better place. Your love and enthusiasm mean everything to me.

Brion Benninger, MD, MBChB, MSc

I thank all the healthcare institutions worldwide and the allopathic and osteopathic associations who have provided me the privilege to wake up each day and focus on how to improve our knowledge of teaching and healing the anatomy of the mind, body, and soul while nurturing humanism. I am grateful and fortunate to have my lovely wife, Alison, and thoughtful son, Jack, support my efforts during late nights and long weekends. Their laughs and experiences complete my life. I thank Elsevier, especially Marybeth Thiel, Elyse O'Grady, and Madelene Hyde for expecting the highest standards and providing guidance, enabling my fellow coeditors to work in a fluid diverse environment. Many thanks to Carlos Machado and Frank Netter: the world is proud. I thank clinicians who trained

me, especially my early gifted surgeon/anatomist/teacher mentors, Drs. Gerald Tressidor and Harold Ellis CBE (Cambridge & Guy's Hospital); Dr. S. Standing and Dr. M. England, who embody professionalism; Drs. P. Crone, E. Szeto, and J. Heatherington, for supporting innovative medical education; my past, current, and future students and patients; and clinical colleagues from all corners of the world who keep medicine and anatomy dynamic, fresh, and wanting. Special thanks to Drs. J.L. Horn, S. Echols, J. Anderson, and J. Underwood, friends, mentors and fellow visionaries who also see "outside the box," challenging the status quo. Heartfelt tribute to my late mentors, friends, and sister, Jim McDaniel, Bill Bryan, and Gail Hendricks, who represent what is good in teaching, caring, and healing. They made this world a wee bit better. Lastly, I thank my mother for her love of education and equality and my father for his inquisitive and creative mind.

Todd M. Hoagland, PhD

It is a privilege to teach clinical human anatomy, and I am eternally grateful to all the body donors and their families for enabling healthcare professionals to train in the dissection laboratory. It is my honor to work with occupational therapy and health professions students and colleagues at Marquette University. I am grateful to John Hansen and the professionals of the Elsevier team for the opportunity to be a steward of the incomparable *Netter Atlas*. Marybeth Thiel and Elyse O'Grady were especially helpful and a pleasure to work with. It was an honor to collaborate with the brilliant Carlos Machado and all the consulting editors. I thank Dave Bolender, Brian Bear, and Rebecca Lufler for being outstanding colleagues, and I thank all the graduate students I've worked with for helping me grow as a person; it is such a pleasure to see them flourish. I am deeply appreciative of Stan Hillman and Jack O'Malley for inspiring me with masterful teaching and rigorous expectations. I am indebted to Gary Kolesari and Richard Hoyt Jr for helping me become a competent clinical anatomist, and to Rob Bouchie for the intangibles and his camaraderie. I am most grateful to my brother, Bill, for his unwavering optimism and for always being there. I thank my mother, Liz, for her dedication and love, and for instilling a strong work ethic. I am humbled by my three awesome children, Ella, Caleb, and Gregory, for helping me redefine love, wonder, and joy. Olya, ty moye solntse!

To Those Who Bequeath Their Bodies to Science

Hic locus est ubi mors gaudet succurrere vitae

“This is the place where death delights in helping life”

—Inscription above the Anatomical Theatre of Bologna

This atlas of human anatomy begins by paying due homage and returning thanks to those who freely bequeath their bodies to anatomy. Such donations testify to an admirable, unselfish, and idealistic sense of sacrifice, and nothing can compensate for the invaluable service rendered to science and to society. Anatomy and medicine owe these individuals a tremendous debt of gratitude. By bequeathing their bodies, they enable students to learn through observation—even now, at the beginning of the twenty-first century, there is no substitute for this. Even beyond death, these altruistic people help the living—students, physicians, and patients alike. This is how the above inscription should be interpreted, and students should endeavor to be worthy of these voluntary and generous donations by respecting the dead as well as by working hard and learning eagerly.

This page was inserted into this eBook by a laruuni and an organ donor.

CONTENTS

7th Edition to 8th Edition Plate Number Conversion Chart Available Online at <https://tinyurl.com/Netter7to8conversion>

SECTION 1 INTRODUCTION • Plates 1–21

General Anatomy • Plates 1–3

- 1 Body Planes and Terms of Relationship
- 2 Body Parts: Anterior View of Female
- 3 Body Parts: Posterior View of Male

Systematic Anatomy • Plates 4–21

- 4 Overview of Nervous System
- 5 Dermatomes of Upper and Lower Limbs
- 6 Sympathetic Nervous System: Schema
- 7 Parasympathetic Nervous System: Schema
- 8 Overview of Skeletal System
- 9 Types of Synovial Joints
- 10 Overview of Muscular System
- 11 Segmental Motor Nerve Function
- 12 Cross Section of Skin
- 13 Overview of Cardiovascular System
- 14 Major Arteries and Pulse Points
- 15 Major Systemic Veins of Cardiovascular System
- 16 Overview of Lymph Vessels and Lymphoid Organs
- 17 Overview of Respiratory System
- 18 Overview of Digestive System
- 19 Overview of Urinary System
- 20 Overview of Reproductive System
- 21 Overview of Endocrine System

Electronic Bonus Plates • Plates BP 1–BP 13

- BP 1 Pilosebaceous Apparatus
- BP 2 Major Body Cavities
- BP 3 Neurons and Synapses
- BP 4 Features of a Typical Peripheral Nerve
- BP 5 Sites of Visceral Referred Pain
- BP 6 Sympathetic Nervous System: General Topography
- BP 7 Parasympathetic Nervous System: General Topography
- BP 8 Cholinergic and Adrenergic Synapses: Schema
- BP 9 Architecture of Bone
- BP 10 Muscle Structure
- BP 11 Joints: Connective Tissues and Articular Cartilage
- BP 12 Cardiovascular System: Composition of Blood
- BP 13 Arterial Wall

SECTION 2 HEAD AND NECK • Plates 22–177

Surface Anatomy • Plates 22–24

- 22 Surface Anatomy of Head and Neck
- 23 Cutaneous Nerves of Head and Neck
- 24 Superficial Arteries and Veins of Face and Scalp

Bones and Joints • Plates 25–47

- 25 Skull: Anterior View
- 26 Skull: Radiographs
- 27 Skull: Lateral View
- 28 Skull: Lateral Radiograph
- 29 Cranium: Median Section
- 30 Calvaria
- 31 Cranial Base: Inferior View
- 32 Cranial Base: Superior View
- 33 Foramina and Canals of Cranial Base: Inferior View
- 34 Foramina and Canals of Cranial Base: Superior View
- 35 Cranium of Newborn
- 36 Bony Framework of Head and Neck
- 37 Nasal Skeleton and Paranasal Sinuses
- 38 Cranium: Posterior and Lateral Views
- 39 Mandible
- 40 Teeth
- 41 Tooth
- 42 Temporomandibular Joint
- 43 Cervical Vertebrae: Atlas and Axis
- 44 Cervical Vertebrae
- 45 Cervical Part of Spinal Column
- 46 External Craniocervical Ligaments
- 47 Internal Craniocervical Ligaments

Neck • Plates 48–58

- 48 Muscles of Facial Expression: Lateral View
- 49 Muscles of Neck: Anterior View
- 50 Superficial Veins of Neck
- 51 Fascial Layers of Neck
- 52 Cervical Fasciae
- 53 Infrahyoid and Suprahyoid Muscles
- 54 Muscles of Neck: Lateral View
- 55 Anterior and Lateral Cervical Muscles
- 56 Nerves of Neck
- 57 Nerves of Neck and Cervical Plexus
- 58 Carotid Arteries

Nose • Plates 59–82

59	Skeleton of Nose
60	Muscles, Nerves, and Arteries of Face
61	Lateral Wall of Nasal Cavity
62	Lateral Wall of Nasal Cavity of Cranium
63	Medial Wall of Nasal Cavity (Nasal Septum)
64	Nerves of Nasal Cavity
65	Vasculature of Nasal Cavity
66	Nerves of Nasal Cavity: Bony Nasal Septum Turned Up
67	Paranasal Sinuses: Paramedian Views
68	Paranasal Sinuses: Changes with Age
69	Paranasal Sinuses: Coronal and Transverse Sections
70	Salivary Glands
71	Facial Nerve Branches and Parotid Gland
72	Muscles of Mastication: Masseter and Temporalis Muscle
73	Muscles of Mastication: Pterygoid Muscles
74	Maxillary Artery
75	Temporal and Infratemporal Fossae
76	Superficial Temporal and Maxillary Arteries
77	Mandibular Nerve (CN V ₃)
78	Infratemporal Fossa
79	Ophthalmic and Maxillary Nerves
80	Autonomic Innervation of Nasal Cavity
81	Nerves and Arteries of Midface
82	Orientation of Nerves and Vessels of Cranial Base

Mouth • Plates 83–90

83	Inspection of Oral Cavity
84	Afferent Innervation of Oral Cavity and Tongue
85	Roof of Oral Cavity
86	Tongue and Salivary Glands: Sections
87	Suprahyoid Muscles
88	Tongue
89	Dorsum of Tongue
90	Fauces

Pharynx • Plates 91–102

91	Posterior View of Pharynx: Nerves and Vessels
92	Muscles of Pharynx: Partially Opened Posterior View
93	Pharynx: Opened Posterior View
94	Pharyngoesophageal Junction
95	Pharynx: Medial View
96	Muscles of Pharynx: Medial View
97	Muscles of Pharynx: Lateral View

98	Nerves of Oral and Pharyngeal Regions
99	Arteries of Head and Neck
100	Veins of Head and Neck
101	Lymph Nodes of Head and Neck
102	Lymph Nodes of Pharynx and Tongue

Larynx and Endocrine Glands • Plates 103–109

103	Thyroid Gland: Anterior View
104	Thyroid Gland: Posterior View
105	Thyroid and Parathyroid Glands
106	Cartilages of Larynx
107	Intrinsic Muscles of Larynx
108	Nerves and Coronal Section of Larynx
109	Action of Intrinsic Muscles of Larynx

Eye • Plates 110–120

110	Eyelids
111	Lacrimal Apparatus
112	Extrinsic Eye Muscles
113	Nerves of Orbit
114	Superior and Anterior Views of Orbit
115	Arteries and Veins of Orbit and Eyelids
116	Eyeball: Transverse Section
117	Anterior and Posterior Chambers of Eyeball
118	Lens and Supporting Structures
119	Intrinsic Arteries and Veins of Eye
120	Vascular Supply of Eye

Ear • Plates 121–126

121	Ear and Course of Sound in Cochlea
122	External Ear and Tympanic Cavity
123	Tympanic Cavity
124	Bony and Membranous Labyrinths
125	Bony and Membranous Labyrinths: Schema and Section
126	Orientation of Labyrinths in Cranium

Brain and Meninges • Plates 127–142

127	Meninges and Diploic Veins
128	Meningeal Arteries
129	Meninges and Superficial Cerebral Veins
130	Dural Venous Sinuses: Sagittal Section
131	Dural Venous Sinuses: Cranial Base
132	Brain: Lateral Views
133	Brain: Medial Views
134	Brain: Inferior View
135	Ventricles of Brain

136	Circulation of Cerebrospinal Fluid
137	Basal Nuclei
138	Thalamus and Related Structures
139	Hippocampus and Fornix
140	Brain Stem
141	Ventricles and Cerebellum
142	Cerebellum

Cranial and Cervical Nerves • Plates 143–162

143	Cranial Nerve Nuclei in Brain Stem: Schema (Posterior View)
144	Cranial Nerve Nuclei in Brain Stem: Schema (Medial View)
145	Cranial Nerves: Schema of Motor and Sensory Distribution
146	Olfactory Nerve (CN I) and Olfactory Pathways: Schema
147	Optic Nerve (CN II) and Visual Pathway: Schema
148	Oculomotor (CN III), Trochlear (CN IV), and Abducens (CN VI) Nerves: Schema
149	Trigeminal Nerve (CN V): Schema
150	Facial Nerve (CN VII): Schema
151	Vestibulocochlear Nerve (CN VIII): Schema
152	Glossopharyngeal Nerve (CN IX): Schema
153	Vagus Nerve (CN X): Schema
154	Accessory Nerve (CN XI): Schema
155	Hypoglossal Nerve (CN XII): Schema
156	Cervical Plexus: Schema
157	Autonomic Nerves in Neck
158	Autonomic Nerves in Head
159	Ciliary Ganglion: Schema
160	Pterygopalatine and Submandibular Ganglia: Schema
161	Otic Ganglion: Schema
162	Taste Pathways: Schema

Cerebral Vasculature • Plates 163–175

163	Arteries to Brain and Meninges
164	Internal Carotid Artery in Petrous Part of Temporal Bone
165	Arteries to Brain: Schema
166	Arteries of Brain: Inferior Views
167	Cerebral Arterial Circle (of Willis)
168	Arteries of Brain: Frontal View and Section
169	Arteries of Brain: Lateral and Medial Views
170	Arteries of Brain: Branches of Vertebral and Basilar Arteries
171	Veins of Posterior Cranial Fossa
172	Deep Veins of Brain
173	Subependymal Veins of Brain
174	Hypothalamus and Hypophysis
175	Vasculature of Hypothalamus and Hypophysis

Regional Imaging • Plates 176–177

- 176 Cranial Imaging (MRA and MRV)
- 177 Cranial Imaging (MRI)

Structures with High Clinical Significance • Tables 2.1–2.4

Cranial Nerves • Tables 2.5–2.8

Branches of Cervical Plexus • Table 2.9

Muscles • Tables 2.10–2.14

Electronic Bonus Plates • Plates BP 14–BP 32

- BP 14 Somatosensory System: Trunk and Limbs
- BP 15 Pyramidal System
- BP 16 3D Skull Reconstruction CTs
- BP 17 Degenerative Changes in Cervical Vertebrae
- BP 18 Atlantooccipital Junction
- BP 19 Muscles of Facial Expression: Anterior View
- BP 20 Musculature of Face
- BP 21 Arteries of Nasal Cavity: Bony Nasal Septum Turned Up
- BP 22 Nose and Maxillary Sinus: Transverse Section
- BP 23 Paranasal Sinuses
- BP 24 Subclavian Artery
- BP 25 Opening of Mandible
- BP 26 Afferent Innervation of Oral Cavity and Pharynx
- BP 27 Fasciae of Orbit and Eyeball
- BP 28 Tympanic Cavity: Medial and Lateral Views
- BP 29 Anatomy of Pediatric Ear
- BP 30 Auditory Tube (Eustachian)
- BP 31 Cranial Imaging (MRV and MRA)
- BP 32 Axial and Coronal MRIs of Brain

SECTION 3 **BACK** • Plates 178–201

Surface Anatomy • Plate 178

- 178 Surface Anatomy of Back

Vertebral Column • Plates 179–185

- 179 Vertebral Column
- 180 Thoracic Vertebrae
- 181 Lumbar Vertebrae
- 182 Vertebrae: Radiograph and MRI
- 183 Sacrum and Coccyx
- 184 Ligaments of Vertebral Column: Lumbosacral Region
- 185 Joints of Vertebral Column: Lumbar Region

Spinal Cord • Plates 186–194

186	Spinal Cord and Spinal Nerves
187	Spinal Nerve Roots and Vertebrae
188	Dermatomes
189	Spinal Meninges and Nerve Roots
190	Spinal Nerve, Roots, and Rami
191	Arteries of Spinal Cord: Schema
192	Arteries of Spinal Cord: Intrinsic Distribution
193	Veins of Spinal Cord and Vertebral Column
194	Veins of Vertebral Column: Vertebral Veins

Muscles and Nerves • Plates 195–199

195	Muscles of Back: Superficial Layer
196	Muscles of Back: Intermediate Layer
197	Muscles of Back: Deep Layer
198	Nerves of Back
199	Nerves of Back of Neck

Cross-Sectional Anatomy • Plates 200–201

200	Lumbar Region of Back: Cross Section
201	Typical Thoracic Spinal Nerve

Structures with High Clinical Significance • Table 3.1

Muscles • Tables 3.2–3.4

Electronic Bonus Plates • Plates BP 33–BP 40

BP 33	Ligaments of Vertebral Column
BP 34	Cervical Spine: Radiographs
BP 35	Cervical Spine: MRI and Radiograph
BP 36	Thoracolumbar Spine: Lateral Radiograph
BP 37	Lumbar Vertebrae: Radiographs
BP 38	Lumbar Spine: MRIs
BP 39	Vertebral Veins: Detail Showing Venous Communications
BP 40	Spinal Cord Cross Sections: Fiber Tracts

SECTION 4 THORAX • Plates 202–266

Surface Anatomy • Plate 202

202	Surface Anatomy of Thorax
-----	---------------------------

Thoracic Skeleton • Plates 203–204

203	Bony Framework of Thorax
204	Ribs and Associated Joints

Mammary Glands • Plates 205–208

- 205 Mammary Glands
- 206 Arteries of Breast
- 207 Lymph Vessels and Lymph Nodes of Breast
- 208 Lymphatic Drainage of Breast

Thoracic Wall and Diaphragm • Plates 209–216

- 209 Anterior Thoracic Wall: Superficial Dissection
- 210 Anterior Thoracic Wall: Deeper Dissection
- 211 Anterior Thoracic Wall: Internal View
- 212 Intercostal Nerves and Arteries
- 213 Veins of Thoracic Wall
- 214 Phrenic Nerve and Relationship to Pericardium
- 215 Diaphragm: Thoracic Surface
- 216 Diaphragm: Abdominal Surface

Lungs, Trachea and Bronchi • Plates 217–230

- 217 Lungs in Thorax: Anterior View
- 218 Lungs in Thorax: Posterior View
- 219 Lungs in Situ: Anterior View
- 220 Great Vessels of Mediastinum
- 221 Lungs: Medial Views
- 222 Bronchial Arteries and Veins
- 223 Bronchopulmonary Segments: Anterior and Posterior Views
- 224 Bronchopulmonary Segments: Medial and Lateral Views
- 225 Trachea and Major Bronchi
- 226 Bronchi and Intrapulmonary Airways
- 227 Intrapulmonary Blood Circulation: Schema
- 228 Lymph Vessels of Thorax and Pulmonary and Mediastinal Lymph Nodes
- 229 Autonomic Nerves of Thorax
- 230 Innervation of Tracheobronchial Tree: Schema

Heart • Plates 231–250

- 231 Heart in Situ
- 232 Heart: Anterior Exposure
- 233 Heart and Precordial Areas of Auscultation
- 234 Heart: Radiographs and CT Angiogram
- 235 Heart: Base and Diaphragmatic Surface
- 236 Pericardial Sac and Pericardial Cavity
- 237 Mediastinum: Cross Section
- 238 Thorax: Coronal Section of Heart and Ascending Aorta
- 239 Coronary Arteries and Cardiac Veins
- 240 Coronary Arteries: Imaging
- 241 Right Atrium and Ventricle
- 242 Left Atrium and Ventricle

243	Valvular Complex of Heart
244	Valvular Complex of Heart (Continued)
245	Atria, Ventricles, and Interventricular Septum
246	Heart Valves
247	Prenatal and Postnatal Circulation
248	Conducting System of Heart
249	Nerves of Thorax
250	Innervation of Heart: Schema

Mediastinum • Plates 251–261

251	Mediastinum: Right Lateral View
252	Mediastinum: Left Lateral View
253	Phrenic Nerve
254	Esophagus in Situ
255	Esophagus: Constrictions and Relations
256	Musculature of Esophagus
257	Esophagogastric Junction
258	Arteries of Esophagus
259	Veins of Esophagus
260	Lymph Vessels and Lymph Nodes of Esophagus
261	Nerves of Esophagus

Cross-Sectional Anatomy • Plates 262–266

262	Thorax: Axial CT Images
263	Cross Section of Thorax at T3 Vertebral Level
264	Cross Section of Thorax at T3/T4 Disc Level
265	Cross Section of Thorax at T4/T5 Disc Level
266	Cross Section of Thorax at T7 Vertebral Level

Structures with High Clinical Significance • Tables 4.1–4.3

Muscles • Table 4.4

Electronic Bonus Plates • Plates BP 41–BP 52

BP 41	Cervical Ribs and Related Variations
BP 42	Muscle Attachments of Ribs
BP 43	Muscles of Respiration
BP 44	Intrapulmonary Airways: Schema
BP 45	Anatomy of Ventilation and Respiration
BP 46	Coronary Arteries: Right Anterolateral Views with Arteriograms
BP 47	Coronary Arteries and Cardiac Veins: Variations
BP 48	Intrinsic Nerves and Variations in Nerves of Esophagus
BP 49	Arteries of Esophagus: Variations
BP 50	Thorax: Coronal Section
BP 51	Thorax: Coronal CTs
BP 52	Innervation of Blood Vessels: Schema

SECTION 5 ABDOMEN • Plates 267–351

Surface Anatomy • Plate 267

267 Surface Anatomy of Abdomen

Abdominal Wall • Plates 268–287

268 Bony Framework of Abdomen
269 Regions and Planes of Abdomen
270 Anterior Abdominal Wall: Superficial Dissection
271 Anterior Abdominal Wall: Intermediate Dissection
272 Anterior Abdominal Wall: Deep Dissection
273 Rectus Sheath: Cross Section
274 Anterior Abdominal Wall: Internal View
275 Posterolateral Abdominal Wall
276 Arteries of Anterior Abdominal Wall
277 Veins of Anterior Abdominal Wall
278 Nerves of Anterior Abdominal Wall
279 Intercostal Nerves
280 Inguinal Region: Dissections
281 Inguinal Canal and Spermatic Cord
282 Femoral Sheath and Inguinal Canal
283 Posterior Abdominal Wall: Internal View
284 Arteries of Posterior Abdominal Wall
285 Veins of Posterior Abdominal Wall
286 Lymph Vessels and Lymph Nodes of Posterior Abdominal Wall
287 Nerves of Posterior Abdominal Wall

Peritoneal Cavity • Plates 288–293

288 Greater Omentum and Abdominal Viscera
289 Mesenteries and Suspensory Muscle of Duodenum
290 Mesocolons and Root of Mesentery
291 Omental Bursa: Stomach Reflected
292 Omental Bursa: Cross Section
293 Peritoneum of Posterior Abdominal Wall

Stomach and Intestines • Plates 294–301

294 Stomach in Situ
295 Mucosa of Stomach
296 Duodenum in Situ
297 Mucosa and Musculature of Small Intestine
298 Ileocecal Junction
299 Cecum and Ileal Orifice
300 Vermiform Appendix
301 Mucosa and Musculature of Large Intestine

Liver, Gallbladder, Pancreas and Spleen • Plates 302–307

- 302 Surfaces and Bed of Liver
- 303 Liver in Situ: Vascular and Duct Systems
- 304 Liver Structure: Schema
- 305 Gallbladder, Extrahepatic Bile Ducts, and Pancreatic Duct
- 306 Pancreas in Situ
- 307 Spleen

Visceral Vasculature • Plates 308–318

- 308 Arteries of Stomach, Liver, and Spleen
- 309 Celiac Trunk and Branches
- 310 Arteries of Liver, Pancreas, Duodenum, and Spleen
- 311 Celiac Arteriogram and CT Angiogram
- 312 Arteries of Duodenum and Head of Pancreas
- 313 Arteries of Small Intestine
- 314 Arteries of Large Intestine
- 315 Veins of Stomach, Duodenum, Pancreas, and Spleen
- 316 Veins of Small Intestine
- 317 Veins of Large Intestine
- 318 Hepatic Portal Vein, Tributaries, and Portacaval Anastomoses

Visceral Nerves and Plexuses • Plates 319–329

- 319 Autonomic Nerves and Ganglia of Abdomen
- 320 Autonomic Innervation of Stomach and Duodenum
- 321 Autonomic Innervation of Stomach and Duodenum (Continued)
- 322 Autonomic Innervation of Small Intestine
- 323 Autonomic Innervation of Large Intestine
- 324 Autonomic Innervation of Intestine: Schema
- 325 Autonomic Innervation of Esophagus, Stomach, and Duodenum: Schema
- 326 Autonomic Reflex Pathways: Schema
- 327 Enteric Plexuses of Intestine
- 328 Autonomic Innervation of Liver: Schema
- 329 Autonomic Innervation of Pancreas: Schema

Kidneys and Suprarenal Glands • Plates 330–343

- 330 Kidneys in Situ: Anterior Views
- 331 Kidneys in Situ: Posterior Views
- 332 Suprarenal Glands
- 333 Gross Structure of Kidney
- 334 Intrarenal Arteries and Renal Segments
- 335 Ureters in Abdomen and Pelvis
- 336 Arteries of Ureters and Urinary Bladder
- 337 Renal Fascia

- 338 Lymph Vessels and Lymph Nodes of Kidneys and Urinary Bladder
- 339 Autonomic Nerves of Kidneys, Ureters, and Urinary Bladder
- 340 Autonomic Innervation of Kidneys and Abdominal Part of Ureters: Schema
- 341 Autonomic Nerves of Suprarenal Glands: Dissection and Schema
- 342 Arteries and Veins of Suprarenal Glands in Situ
- 343 Abdominal Wall and Viscera: Paramedian Section

Lymphatics • Plates 344

- 344 Lymphatic Drainage of Abdomen and Pelvis: Schema

Regional Imaging • Plates 345–346

- 345 Abdominal Scans: Axial CT Images
- 346 Abdominal Scans: Axial CT Images (Continued)

Cross-Sectional Anatomy • Plates 347–351

- 347 Cross Section at T10 Vertebral Level, Through Esophagogastric Junction
- 348 Cross Section at T12 Vertebral Level, Inferior to Xiphoid Process
- 349 Cross Section at T12/L1 Disc Level
- 350 Cross Section at L1/L2 Disc Level
- 351 Cross Section at L3/L4 Disc Level

Structures with High Clinical Significance • Tables 5.1–5.3

Muscles • Table 5.4

Electronic Bonus Plates • Plates BP 53–BP 83

- BP 53 Inguinal and Femoral Regions
- BP 54 Indirect Inguinal Hernia
- BP 55 Variations in Position and Contour of Stomach in Relation to Body Habitus
- BP 56 Layers of Duodenal Wall
- BP 57 CT and MRCP Showing Appendix, Gallbladder, and Ducts; Nerve Branches of Hepatic Artery
- BP 58 Topography of Liver
- BP 59 Variations in Form of Liver
- BP 60 Sigmoid Colon: Variations in Position
- BP 61 Variations in Arterial Supply to Cecum and Posterior Peritoneal Attachment of Cecum
- BP 62 Variations in Pancreatic Duct
- BP 63 Variations in Cystic, Hepatic, and Pancreatic Ducts
- BP 64 Variations in Cystic Arteries
- BP 65 Variations in Hepatic Arteries

- BP 66 Variations and Anomalies of Hepatic Portal Vein
- BP 67 Variations in Celiac Trunk
- BP 68 Variations in Colic Arteries
- BP 69 Variations in Colic Arteries (Continued)
- BP 70 Variations in Renal Artery and Vein
- BP 71 Histology of Renal Corpuscle
- BP 72 Nephron and Collecting Tubule: Schema
- BP 73 Blood Vessels in Parenchyma of Kidney: Schema
- BP 74 Lymph Vessels and Lymph Nodes of Stomach
- BP 75 Lymph Vessels and Lymph Nodes of Pancreas
- BP 76 Lymph Vessels and Lymph Nodes of Small Intestine
- BP 77 Lymph Vessels and Lymph Nodes of Large Intestine
- BP 78 Lymph Vessels and Lymph Nodes of Liver
- BP 79 Schematic Cross Section of Abdomen at T12 Vertebral Level
- BP 80 Transverse Section of Abdomen: L5 Vertebral Level, Near Transtubercular Plane
- BP 81 Transverse Section of Abdomen: S1 Vertebral Level, Anterior Superior Iliac Spine
- BP 82 Axial CT Image of Upper Abdomen
- BP 83 Arterial Variations and Collateral Supply of Liver and Gallbladder

SECTION 6 PELVIS • Plates 352–421

Surface Anatomy • Plate 352

- 352 Surface Anatomy of Pelvis

Bony Pelvis • Plates 353–357

- 353 Bony Framework of Pelvis
- 354 Male and Female Pelvis: Radiographs
- 355 Sex Differences of Bony Pelvis: Measurements
- 356 Ligaments of Bony Pelvis
- 357 Ligaments of Hip Bone

Pelvic Diaphragm and Viscera • Plates 358–368

- 358 Pelvic Diaphragm: Female
- 359 Pelvic Diaphragm (Female): Medial and Superior Views
- 360 Pelvic Diaphragm (Female): Inferior Views
- 361 Pelvic Diaphragm (Male): Superior View
- 362 Pelvic Diaphragm (Male): Inferior View
- 363 Pelvic Cavity: Female
- 364 Pelvic Viscera and Perineum: Female
- 365 Female Internal Genital Organs
- 366 Endopelvic Fascia
- 367 Pelvic Cavity: Male
- 368 Pelvic Viscera and Perineum: Male

Urinary Bladder • Plates 369–371

- 369 Urinary Bladder: Orientation and Supports
- 370 Female Urethral Sphincters
- 371 Urinary Bladder: Female and Male

Female Internal Genitalia • Plates 372–376

- 372 Uterus, Vagina, and Supporting Structures
- 373 Uterus: Fascial Ligaments
- 374 Uterus and Adnexa
- 375 Pelvic Viscera: Female
- 376 Pelvic Ligaments

Female Perineum and External Genitalia • Plates 377–380

- 377 Female Perineum and External Genitalia
- 378 Female Perineum (Superficial Dissection)
- 379 Female Perineum (Deeper Dissection)
- 380 Female Perineal Spaces

Male Perineum and External Genitalia • Plates 381–388

- 381 Male Perineum and External Genitalia (Superficial Dissection)
- 382 Male Perineum and External Genitalia (Deeper Dissection)
- 383 Penis
- 384 Male Perineal Spaces
- 385 Prostate and Seminal Gland
- 386 Urethra
- 387 Descent of Testis
- 388 Scrotum and Contents

Homologies of Male and Female Genitalia • Plates 389–390

- 389 Homologues of External Genitalia
- 390 Homologues of Internal Genitalia

Male Internal Genitalia • Plates 391–392

- 391 Testes
- 392 Testis, Epididymis, and Ductus Deferens

Rectum and Anal Canal • Plates 393–399

- 393 Rectum in Situ: Female and Male
- 394 Ischioanal Fossae
- 395 Rectum and Anal Canal
- 396 Anorectal Musculature
- 397 External Anal Sphincter: Perineal Views
- 398 Perineal and Pelvic Extraperitoneal Spaces: Actual and Potential
- 399 Pelvic Scans: Sagittal T2-Weighted MRIs

Vasculature • Plates 400–410

- 400 Arteries of Rectum and Anal Canal: Male Posterior View
- 401 Veins of Rectum and Anal Canal: Female Anterior View
- 402 Arteries and Veins of Pelvic Viscera: Female Anterior View
- 403 Arteries and Veins of Testis: Anterior View
- 404 Arteries of Pelvis: Female
- 405 Arteries and Veins of Pelvis: Male
- 406 Arteries and Veins of Perineum and Uterus
- 407 Arteries and Veins of Perineum: Male
- 408 Lymph Vessels and Lymph Nodes of Pelvis and Genitalia: Female
- 409 Inguinal Nodes and Lymph Vessels of Perineum: Female
- 410 Lymph Vessels and Lymph Nodes of Pelvis and Genitalia: Male

Nerves of Perineum and Pelvic Viscera • Plates 411–419

- 411 Nerves of External Genitalia: Male
- 412 Nerves of Pelvic Viscera: Male
- 413 Nerves of Perineum: Male
- 414 Nerves of Pelvic Viscera: Female
- 415 Nerves of Perineum and External Genitalia: Female
- 416 Neuropathways in Parturition
- 417 Innervation of Female Reproductive Organs: Schema
- 418 Innervation of Male Reproductive Organs: Schema
- 419 Innervation of Urinary Bladder and Lower Ureter: Schema

Cross-Sectional Anatomy • Plates 420–421

- 420 Male Pelvis: Cross Section of Bladder–Prostate Junction
- 421 Female Pelvis: Cross Section of Vagina and Urethra

Structures with High Clinical Significance • Tables 6.1–6.3

Muscles • Table 6.4

Electronic Bonus Plates • Plates BP 84–BP 95

- BP 84 Fasciae of Pelvis and Perineum: Male and Female
- BP 85 Cystourethrograms: Male and Female
- BP 86 Female Urethra
- BP 87 Genetics of Reproduction
- BP 88 Menstrual Cycle
- BP 89 Uterine Development
- BP 90 Ovary, Oocytes, and Follicles
- BP 91 Variations in Hymen
- BP 92 Cross Section of Pelvis Through Prostate
- BP 93 Arteries and Veins of Pelvis: Male (Featuring Prostate)
- BP 94 Cross Section of Lower Pelvis
- BP 95 Endocrine Glands, Hormones, and Puberty

SECTION 7 UPPER LIMB • Plates 422–490

Surface Anatomy • Plates 422–426

- 422 Surface Anatomy of Upper Limb
- 423 Cutaneous Innervation of Upper Limb
- 424 Superficial Veins of Proximal Upper Limb
- 425 Superficial Veins of Forearm and Hand
- 426 Lymph Vessels and Lymph Nodes of Upper Limb

Shoulder and Axilla • Plates 427–439

- 427 Humerus and Scapula
- 428 Muscle Attachment Sites of Humerus, Scapula, and Clavicle
- 429 Clavicle and Sternoclavicular Joint
- 430 Shoulder: Anteroposterior Radiograph
- 431 Joints of Shoulder
- 432 Muscles of Shoulder
- 433 Axilla: Posterior Wall
- 434 Rotator Cuff Muscles
- 435 Pectoral, Clavipectoral, and Axillary Fasciae
- 436 Shoulder Region
- 437 Axillary Artery and Anastomoses Around Scapula
- 438 Axilla: Anterior View
- 439 Brachial Plexus: Schema

Arm • Plates 440–445

- 440 Muscles of Arm: Anterior Compartment
- 441 Muscles of Arm: Posterior Compartment
- 442 Brachial Artery in Situ
- 443 Arteries of Upper Limb
- 444 Veins of Upper Limb
- 445 Arm: Serial Cross Sections

Elbow and Forearm • Plates 446–461

- 446 Bones of Elbow
- 447 Elbow: Radiographs
- 448 Ligaments of Elbow
- 449 Bones of Forearm
- 450 Muscles of Forearm: Pronators and Supinator
- 451 Muscles of Forearm: Extensors of Wrist and Digits
- 452 Muscles of Forearm: Flexors of Wrist
- 453 Muscles of Forearm: Flexors of Digits
- 454 Muscles of Forearm: Superficial Part of Posterior Compartment
- 455 Muscles of Forearm: Deep Part of Posterior Compartment

456	Muscles of Forearm: Superficial Part of Anterior Compartment
457	Muscles of Forearm: Anterior Compartment
458	Muscles of Forearm: Deep Part of Anterior Compartment
459	Attachments of Muscles of Forearm: Anterior View
460	Attachments of Muscles of Forearm: Posterior View
461	Forearm: Serial Cross Sections

Wrist and Hand • Plates 462–481

462	Carpal Bones
463	Movements of Wrist
464	Ligaments of Wrist: Anterior View
465	Ligaments of Wrist: Posterior View
466	Bones of Hand
467	Wrist and Hand: Radiographs
468	Metacarpophalangeal and Interphalangeal Ligaments
469	Wrist and Hand: Superficial Palmar Dissections
470	Wrist and Hand: Deeper Palmar Dissections
471	Lumbrical Muscles, Midpalmar and Thenar Spaces, and Tendon Sheaths
472	Flexor Tendons, Arteries, and Nerves at Wrist
473	Spaces and Tendon Sheaths of Hand
474	Flexor and Extensor Tendons in Fingers
475	Muscles of Hand
476	Arteries of Hand: Palmar Views
477	Wrist and Hand: Superficial Lateral Dissection
478	Wrist and Hand: Superficial Dorsal Dissection
479	Nerves and Arteries of Dorsal Hand and Wrist
480	Extensor Tendons at Wrist
481	Fingers

Nerves and Vasculature • Plates 482–489

482	Cutaneous Innervation of Wrist and Hand
483	Arteries and Nerves of Upper Limb: Anterior View
484	Nerves of Upper Limb
485	Musculocutaneous Nerve
486	Median Nerve
487	Ulnar Nerve
488	Radial Nerve in Arm and Nerves of Posterior Shoulder
489	Radial Nerve in Forearm and Hand

Regional Imaging • Plate 490

490	Shoulder MRI and CT
-----	---------------------

Structures with High Clinical Significance • Tables 7.1–7.2

Nerves of Brachial Plexus • Tables 7.3–7.4

Muscles • Tables 7.5–7.8

Electronic Bonus Plates • Plates BP 96–BP 102

- BP 96 Arteries of Arm and Proximal Forearm
- BP 97 Arteries of Forearm and Hand
- BP 98 Ligaments of Wrist: Posterior and Anterior Views
- BP 99 Flexor and Extensor Zones of Hand
- BP 100 Cross Sections Through Metacarpal and Distal Carpal Bones
- BP 101 Cross Section of Hand: Axial View
- BP 102 Cross Section of Hand: Axial View (Continued)

SECTION 8 LOWER LIMB • Plates 491–556

Surface Anatomy • Plates 491–494

- 491 Surface Anatomy of Lower Limb
- 492 Superficial Veins of Lower Limb: Anterior View
- 493 Superficial Veins of Lower Limb: Posterior View
- 494 Lymph Vessels and Lymph Nodes of Lower Limb

Hip, Buttock, and Thigh • Plates 495–515

- 495 Hip Bone
- 496 Hip Joint
- 497 Hip Joint: Anteroposterior Radiograph
- 498 Attachments of Muscles of Hip and Thigh: Anterior View
- 499 Attachments of Muscles of Hip and Thigh: Posterior View
- 500 Femur
- 501 Muscles of Hip and Thigh: Lateral View
- 502 Muscles of Thigh: Anterior Compartment
- 503 Muscles of Thigh: Medial Compartment
- 504 Muscles of Hip and Thigh: Posterior Views
- 505 Psoas and Iliacus Muscle
- 506 Lumbosacral Plexuses
- 507 Lumbar Plexus
- 508 Sacral and Coccygeal Plexuses
- 509 Arteries of Thigh: Anterior Views
- 510 Arteries of Thigh: Anterior View of Deeper Dissection
- 511 Arteries of Thigh: Posterior View
- 512 Nerves of Buttock
- 513 Hip Bursae: Posterior and Anterolateral Views
- 514 Arteries of Femoral Head and Neck
- 515 Thigh: Serial Cross Sections

Knee • Plates 516–523

516	Knee: Medial and Lateral Views
517	Knee: Anterior Views
518	Knee: Interior Views
519	Knee: Cruciate and Collateral Ligaments
520	Knee: Anteroposterior Radiograph and Posterior View
521	Knee: Posterior and Sagittal Views
522	Arteries of Lower Limb
523	Veins of Lower Limb

Leg • Plates 524–534

524	Tibia and Fibula: Anterior and Posterior Views
525	Tibia and Fibula: Additional Views and Cross Section
526	Attachments of Muscles of Leg
527	Muscles of Leg: Superficial Part of Posterior Compartment
528	Muscles of Leg: Superficial Part of Posterior Compartment (Partial Dissection)
529	Muscles of Leg: Deep Part of Posterior Compartment
530	Muscles of Leg: Lateral Compartment
531	Muscles of Leg: Anterior Compartment
532	Muscles of Leg: Anterior Compartment (Continued)
533	Veins of Leg
534	Leg: Cross Sections and Compartments

Ankle and Foot • Plates 535–549

535	Bones of Foot: Superior and Inferior Views
536	Bones of Foot: Lateral View
537	Calcaneus
538	Ligaments of Ankle and Foot
539	Ligaments of Foot: Plantar View
540	Tendon Sheaths of Ankle
541	Muscles of Dorsum of Foot: Superficial Dissection
542	Muscles of Dorsum of Foot: Deep Dissection
543	Sole of Foot: Superficial Dissection
544	Muscles of Sole of Foot: First Layer
545	Muscles of Sole of Foot: Second Layer
546	Muscles of Sole of Foot: Third Layer
547	Interosseous Muscles and Deep Arteries of Foot
548	Interosseous Muscles of Foot
549	Cross Section of Foot

Nerves • Plates 550–554

550	Femoral Nerve and Lateral Femoral Cutaneous Nerve
551	Obturator Nerve
552	Sciatic Nerve and Posterior Femoral Cutaneous Nerve
553	Tibial Nerve
554	Common Fibular Nerve

Regional Imaging • Plates 555–556

- 555 Hip: MRI and 3D CT
- 556 Ankle: Radiographs

Structures with High Clinical Significance • Tables 8.1–8.2

Nerves of Lumbosacral Plexus • Tables 8.3–8.4

Muscles • Tables 8.5–8.8

Electronic Bonus Plates • Plates BP 103–BP 112

- BP 103 Arteries of Knee and Foot
- BP 104 Cross-Sectional Anatomy of Hip: Axial View
- BP 105 Arteries of Thigh and Knee
- BP 106 Leg: Serial Cross Sections
- BP 107 Osteology of Knee
- BP 108 Knee Radiograph: Lateral View
- BP 109 Foot: Nerves and Arteries
- BP 110 Cross-Sectional Anatomy of Ankle and Foot
- BP 111 Cross-Sectional Anatomy of Foot
- BP 112 Anatomy of Toenail

References

Index

Available Online (see inside front cover)

- Bonus Plates
- Study Guides
- Self-Assessments

APPENDIXES

e-Appendix A: Plate Pearls

e-Appendix B: Study Guides

INTRODUCTION

1

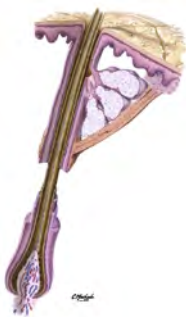General Anatomy
Systematic Anatomy

1–3
4–21

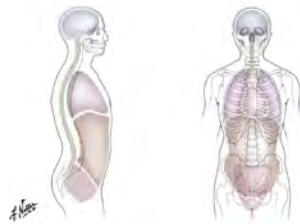Electronic Bonus Plates

BP 1–BP 13

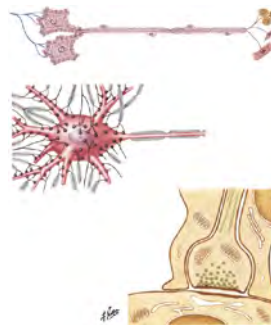
ELECTRONIC BONUS PLATES



BP 1 Pilosebaceous Apparatus



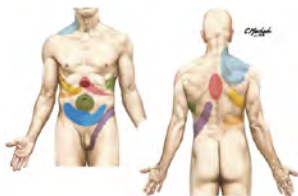BP 2 Major Body Cavities



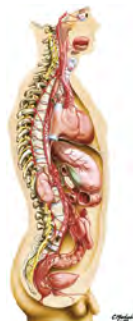BP 3 Neurons and Synapses



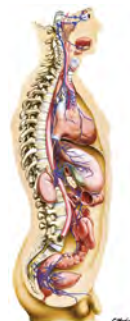BP 4 Features of a Typical Peripheral Nerve



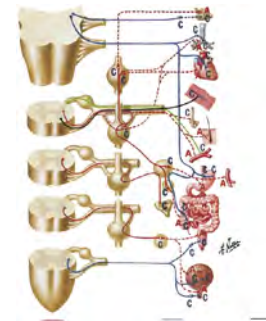
BP 5 Sites of Visceral Referred Pain



BP 6 Sympathetic Nervous System: General Topography

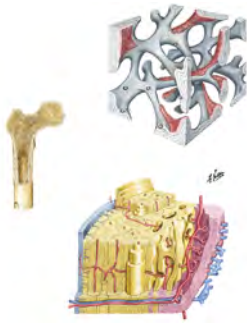
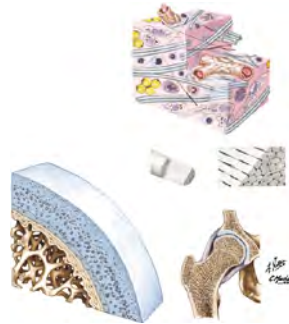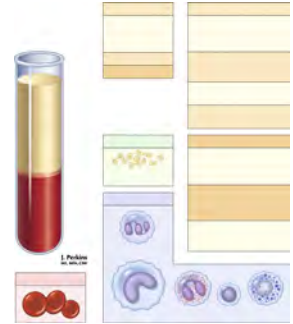

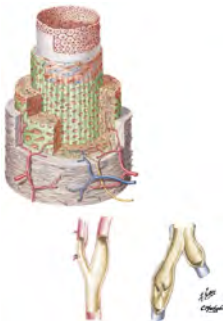
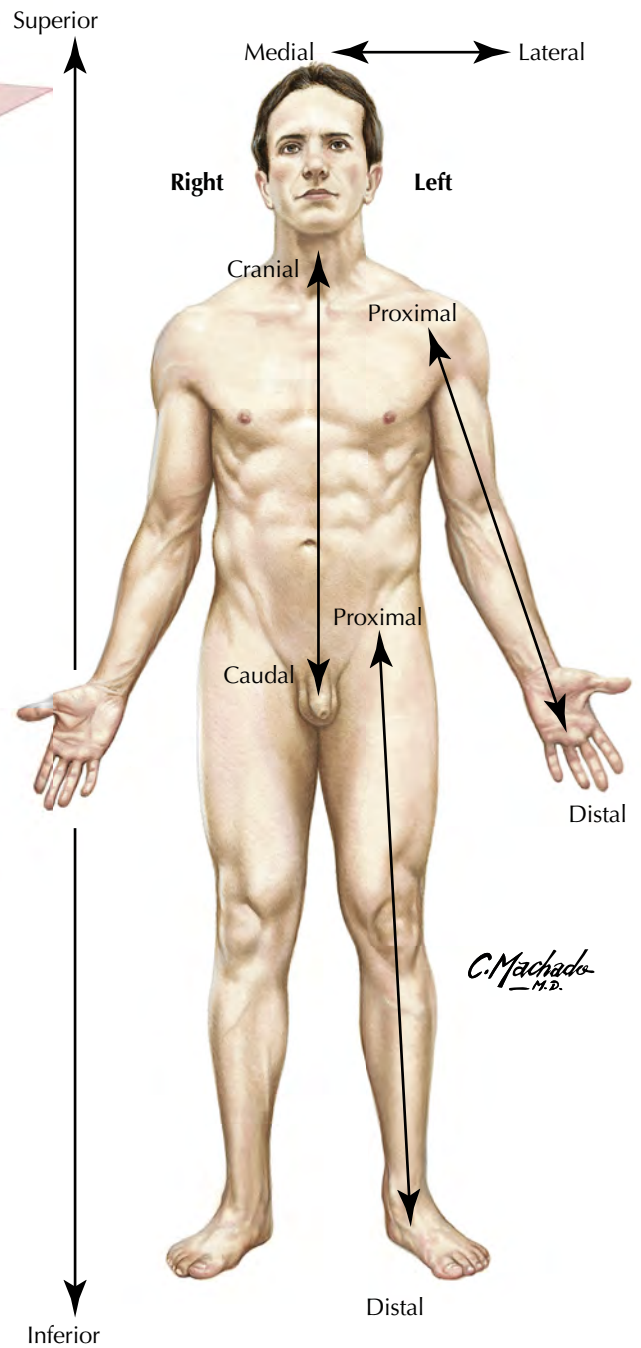
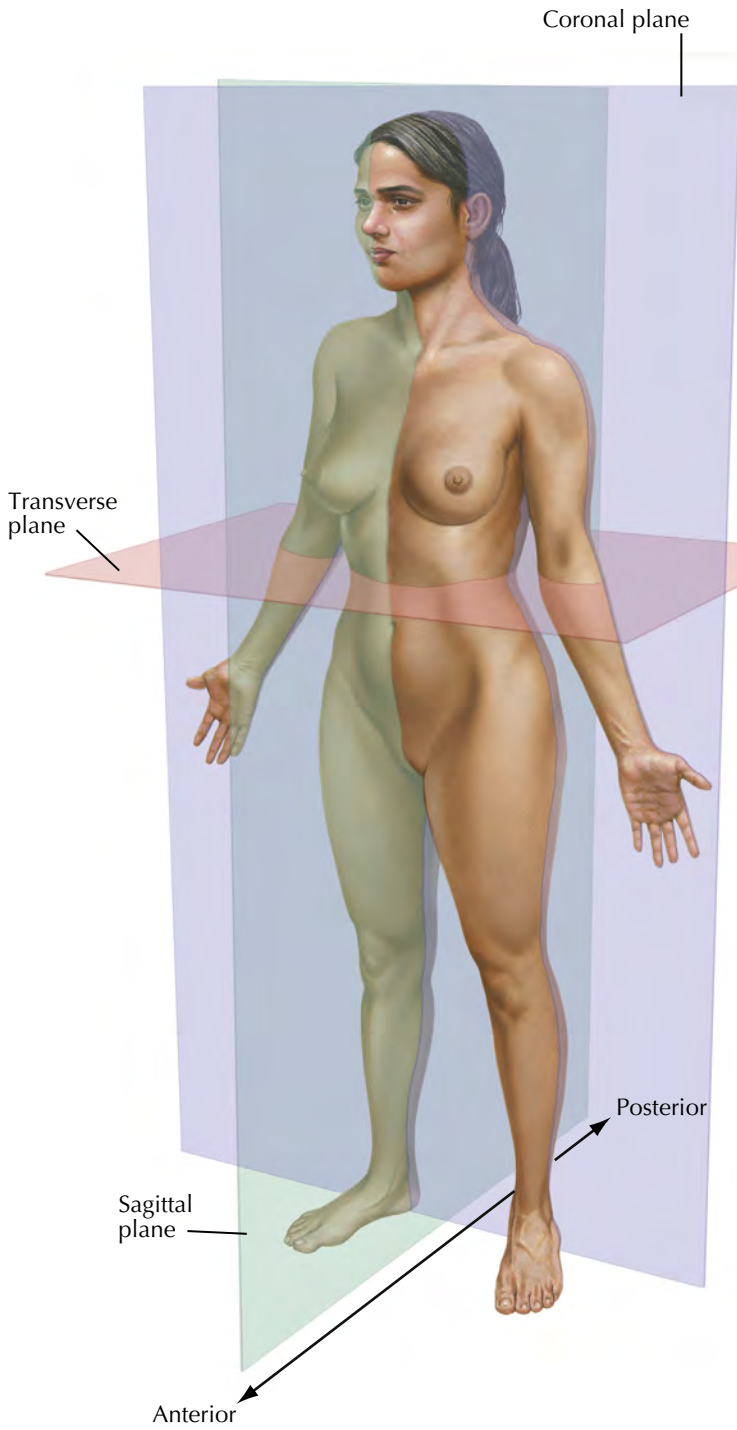
BP 7 Parasympathetic Nervous System: General Topography



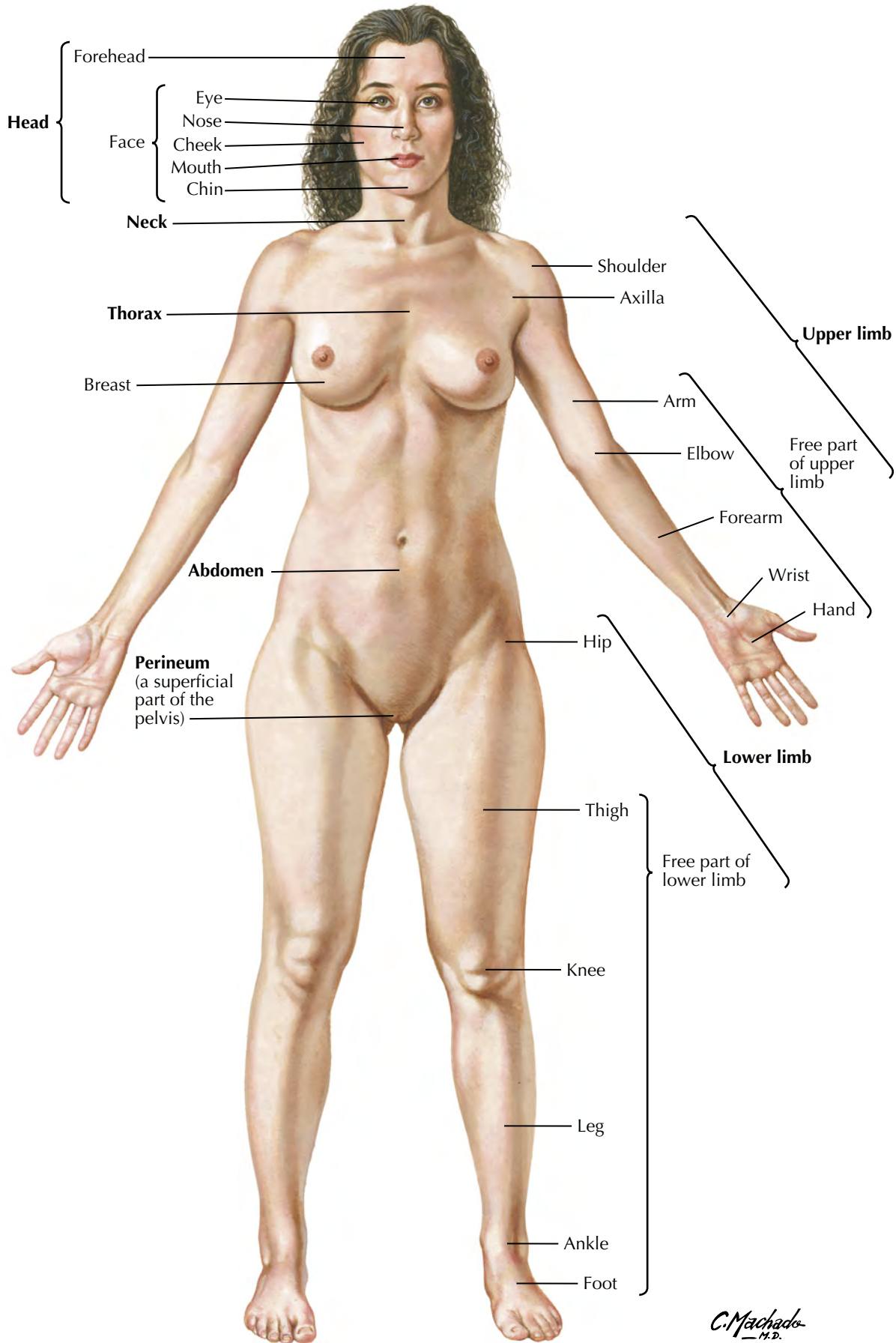
BP 8 Cholinergic and Adrenergic Synapses: Schema

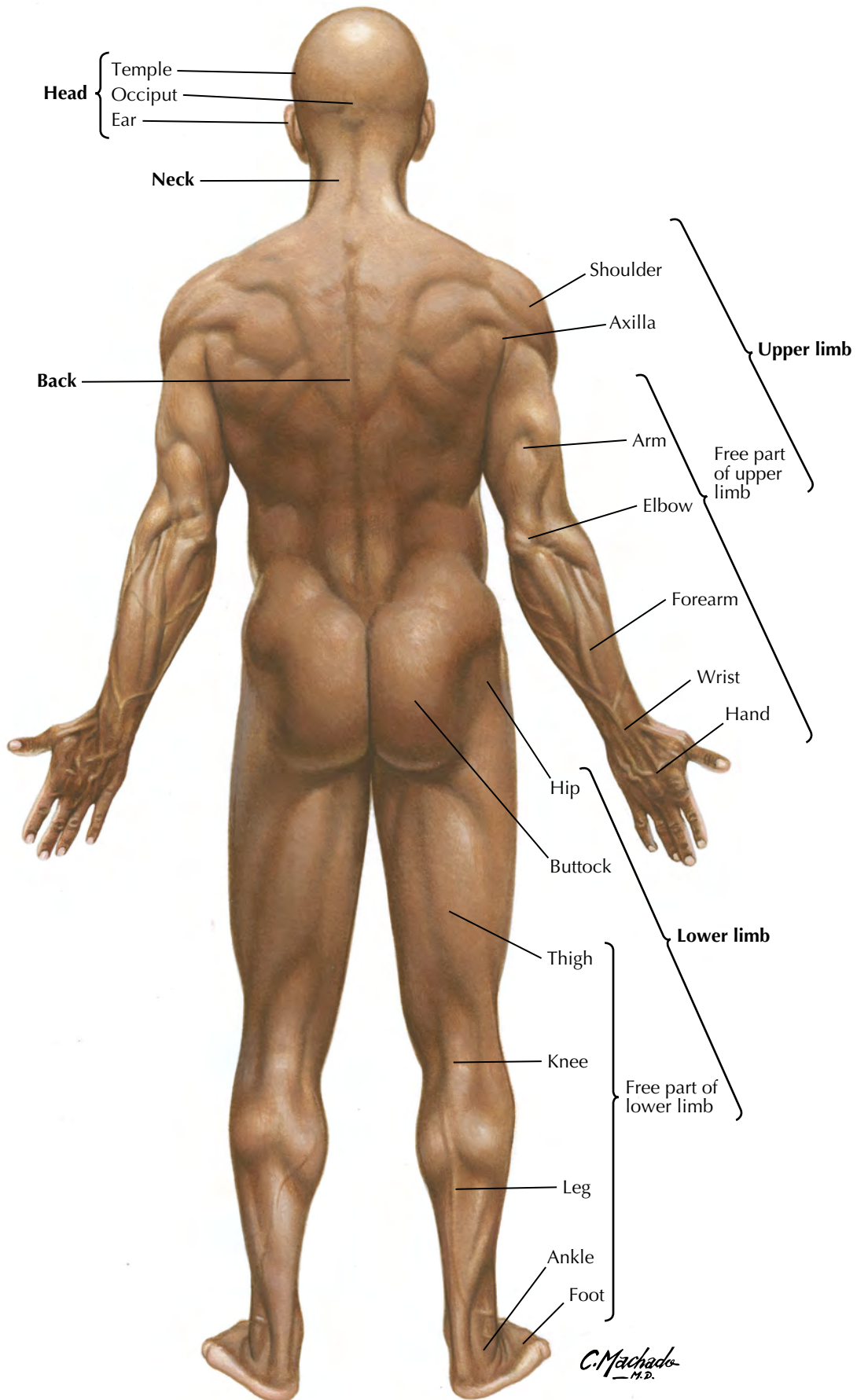
ELECTRONIC BONUS PLATES—*cont'd*

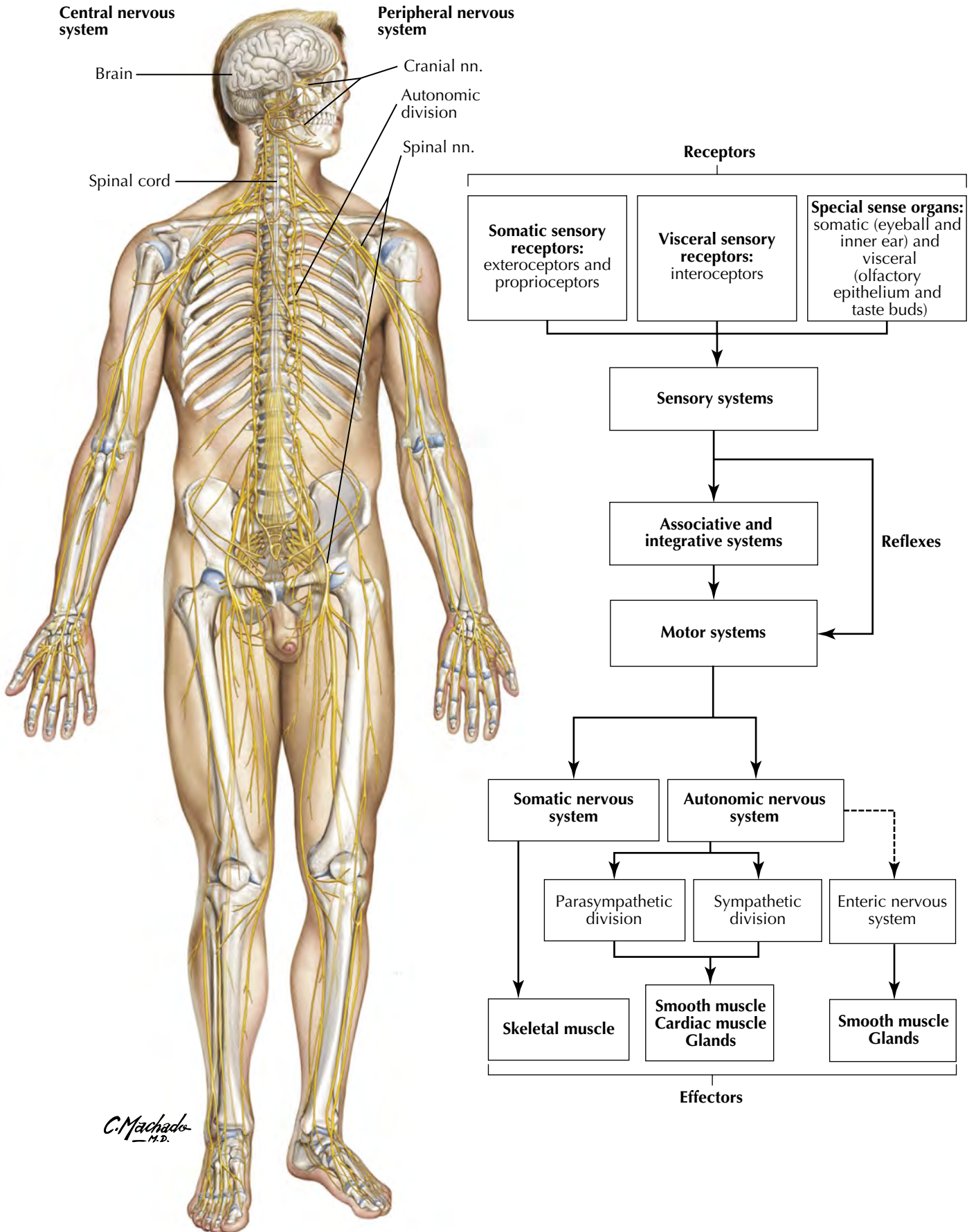
**BP 9** Architecture of Bone**BP 10** Muscle Structure**BP 11** Joints: Connective Tissues and Articular Cartilage**BP 12** Cardiovascular System: Composition of Blood**BP 13** Arterial Wall

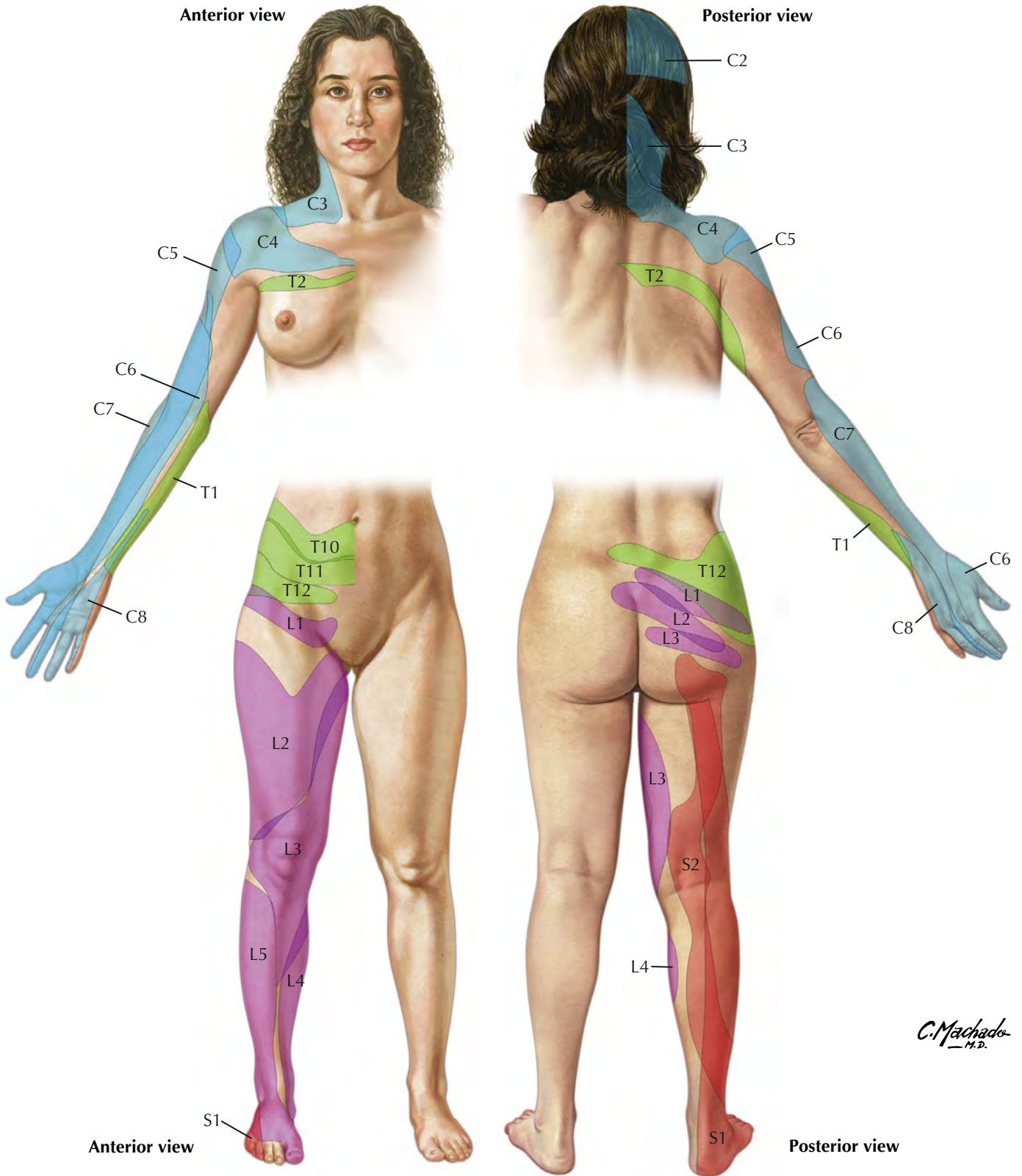


Body Parts: Anterior View of Female





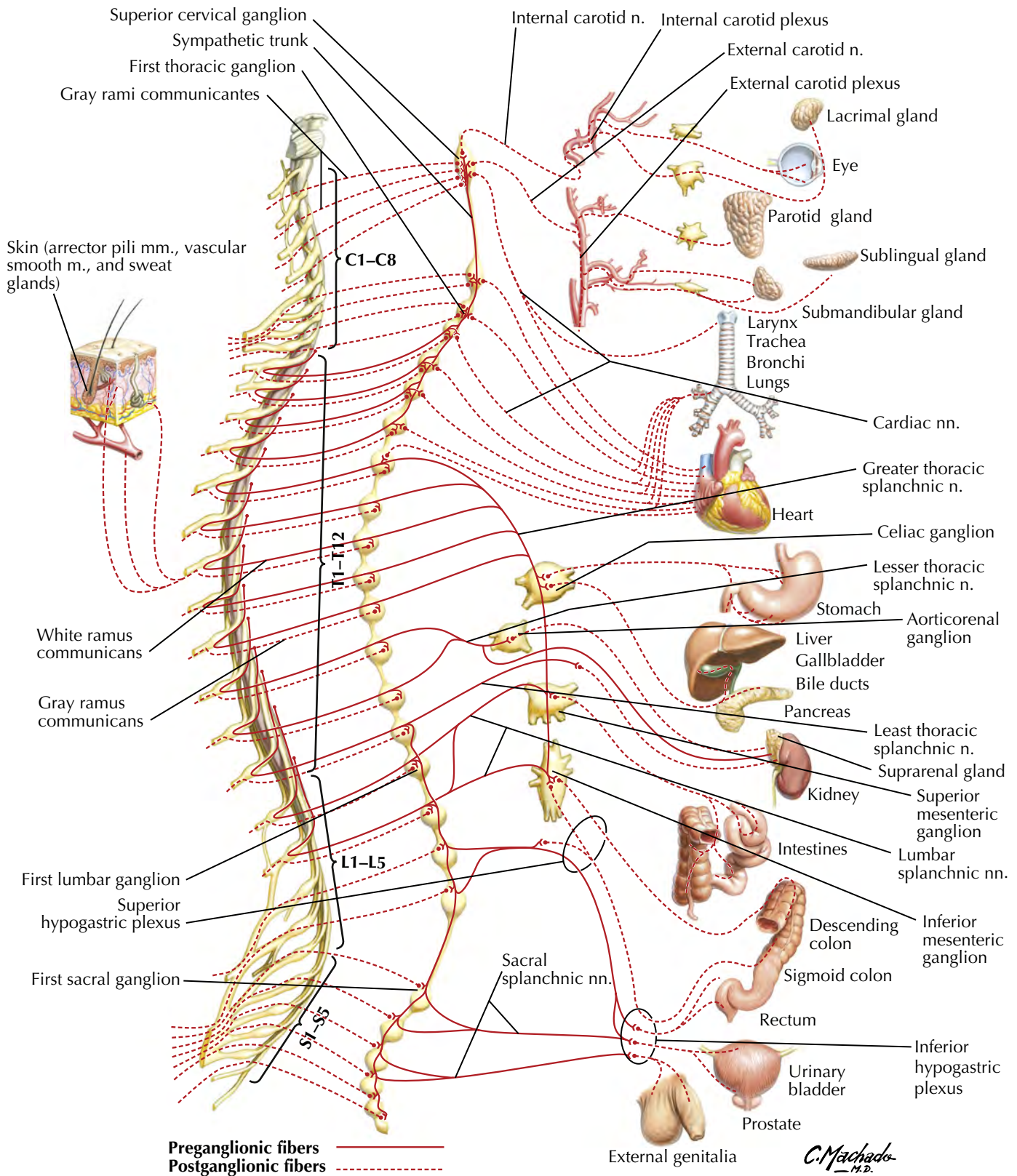


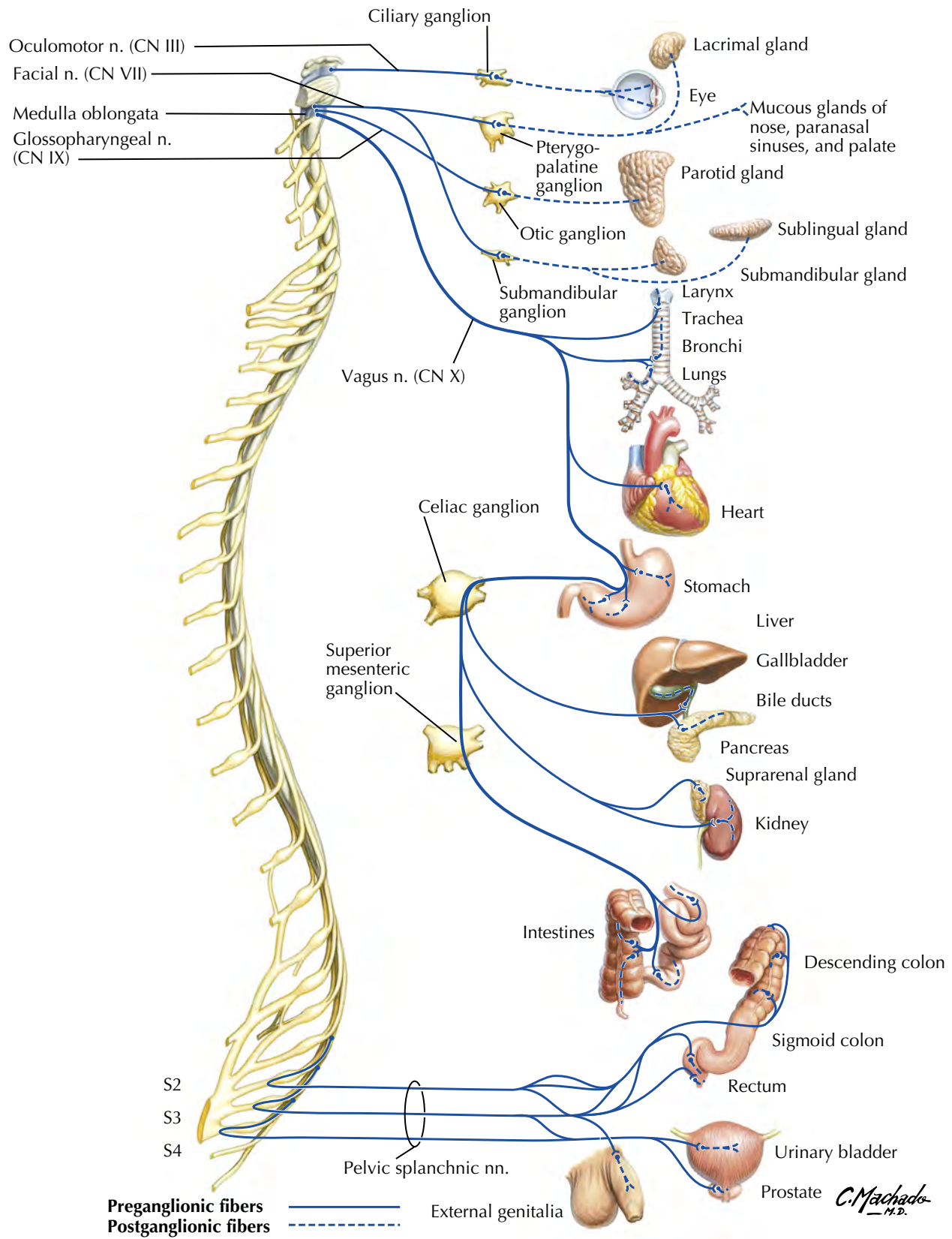


Schematic based on Lee MW, McPhee RW, Stringer MD. An evidence-based approach to human dermatomes. *Clin Anat.* 2008;21(5):363–373. doi: 10.1002/ca.20636. PMID: 18470936. Please note that these areas are not absolute and vary from person to person. S3, S4, S5, and Co supply the perineum but are not shown for reasons of clarity. Of note, the dermatomes are larger than illustrated as the figure is based on best evidence; gaps represent areas in which the data are inconclusive.

Sympathetic Nervous System: Schema

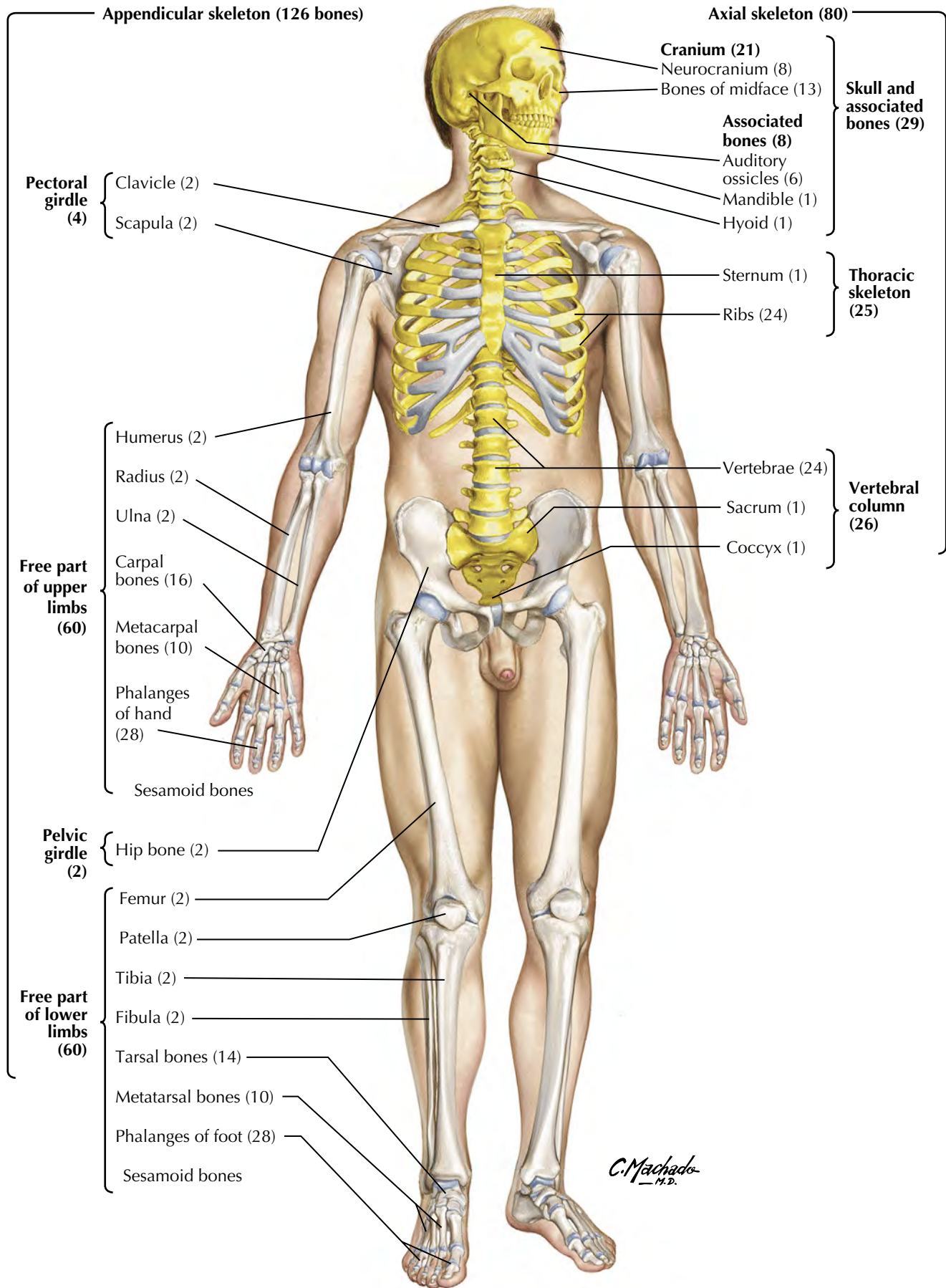
See also Plates 229, 249, 341, BP 6, BP 8, BP 52



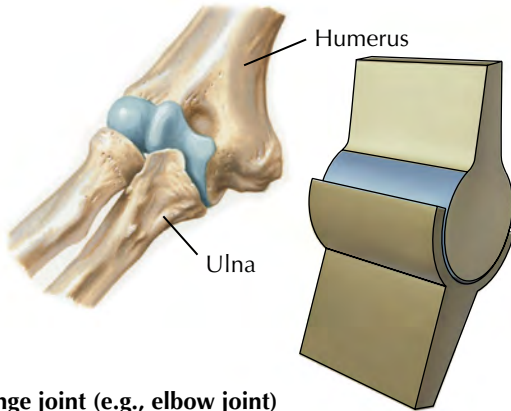
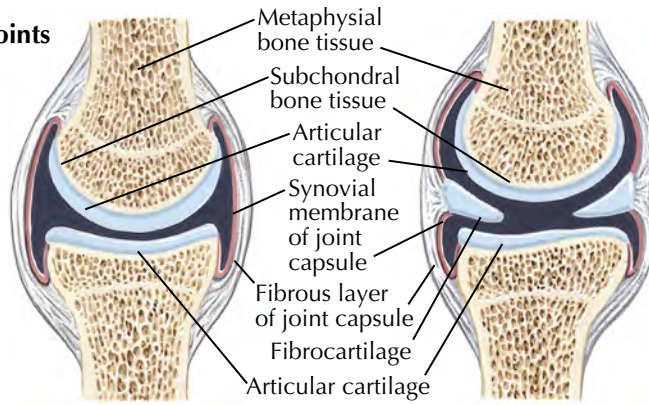


Overview of Skeletal System

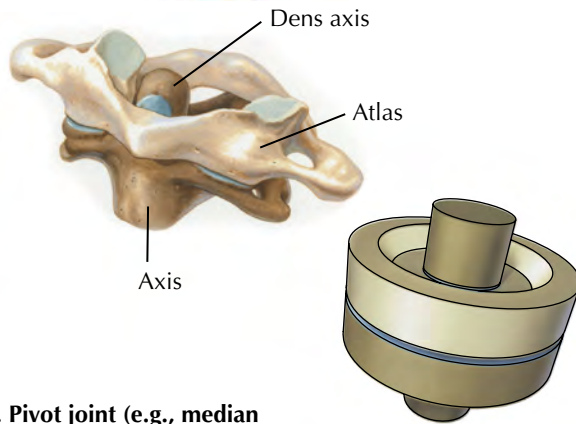
See also Plate BP 9



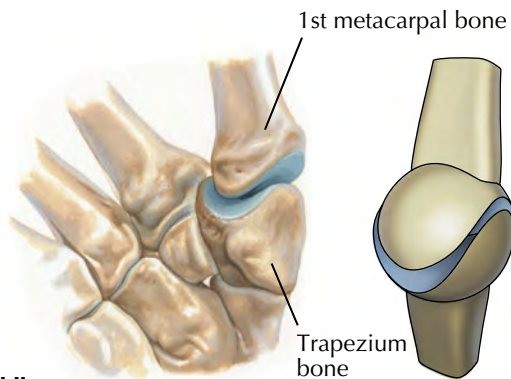
Structure of synovial joints



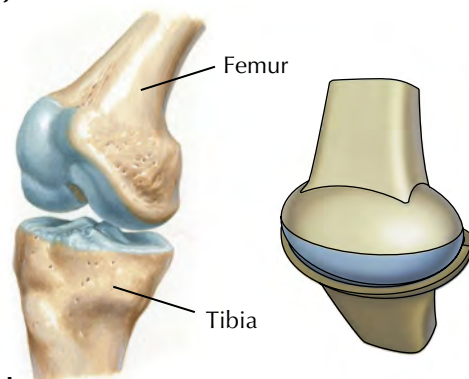
A. Hinge joint (e.g., elbow joint)



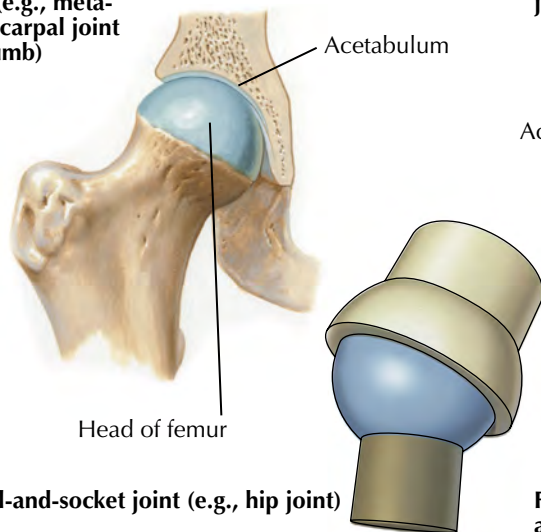
B. Pivot joint (e.g., median atlantoaxial joint)



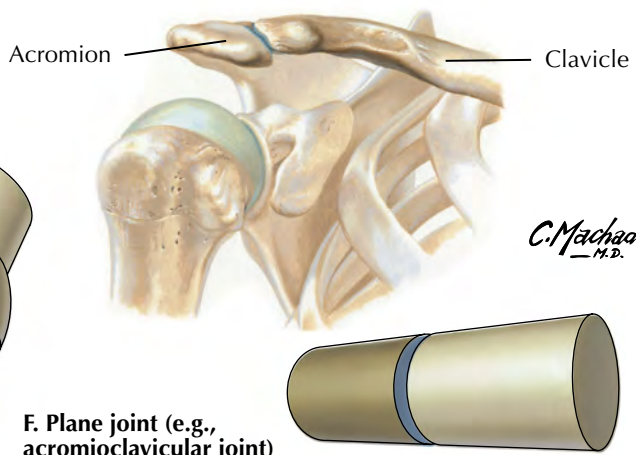
C. Saddle joint (e.g., metacarpophalangeal joint of thumb)



D. Condylloid joint (e.g., knee joint)

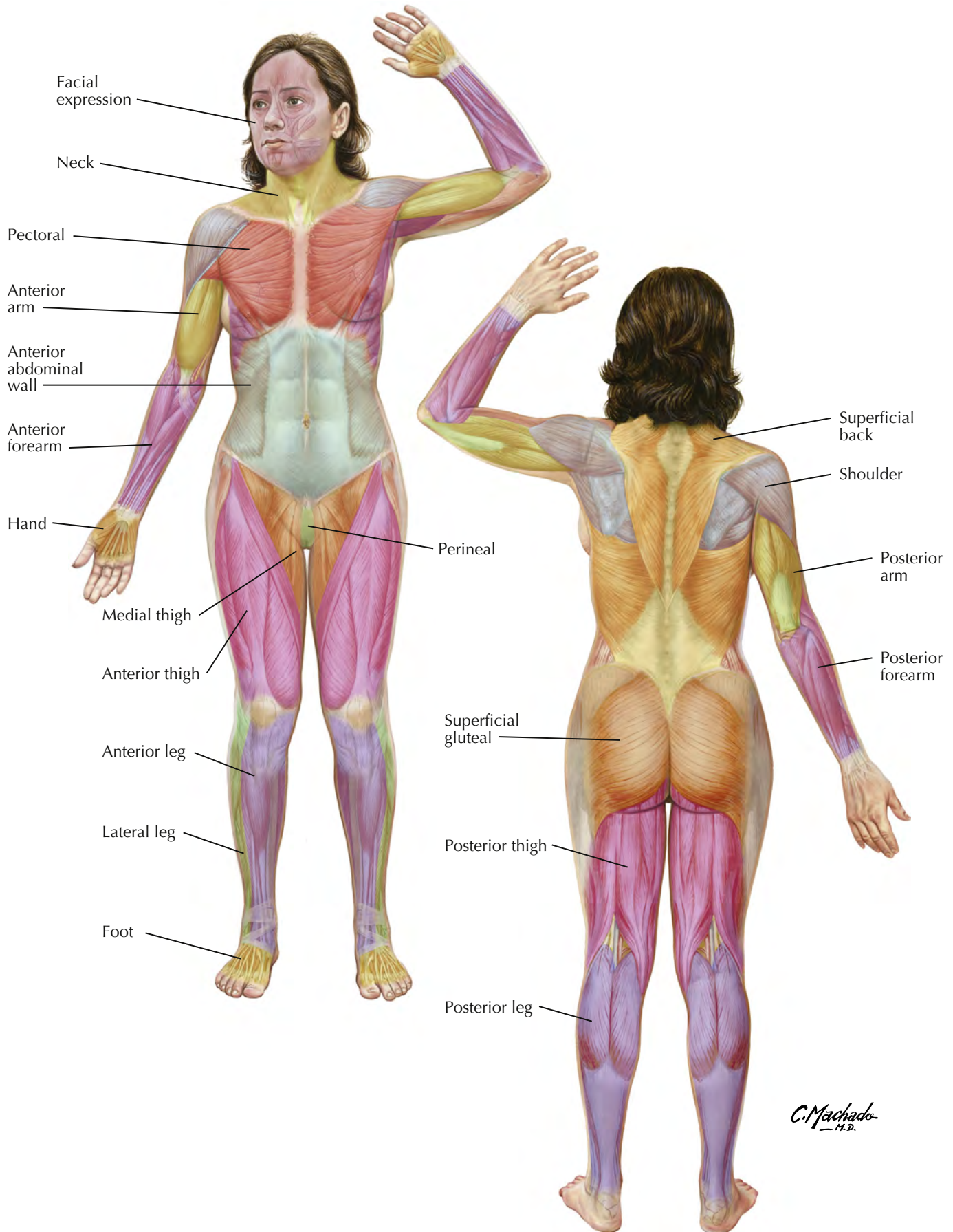


E. Ball-and-socket joint (e.g., hip joint)

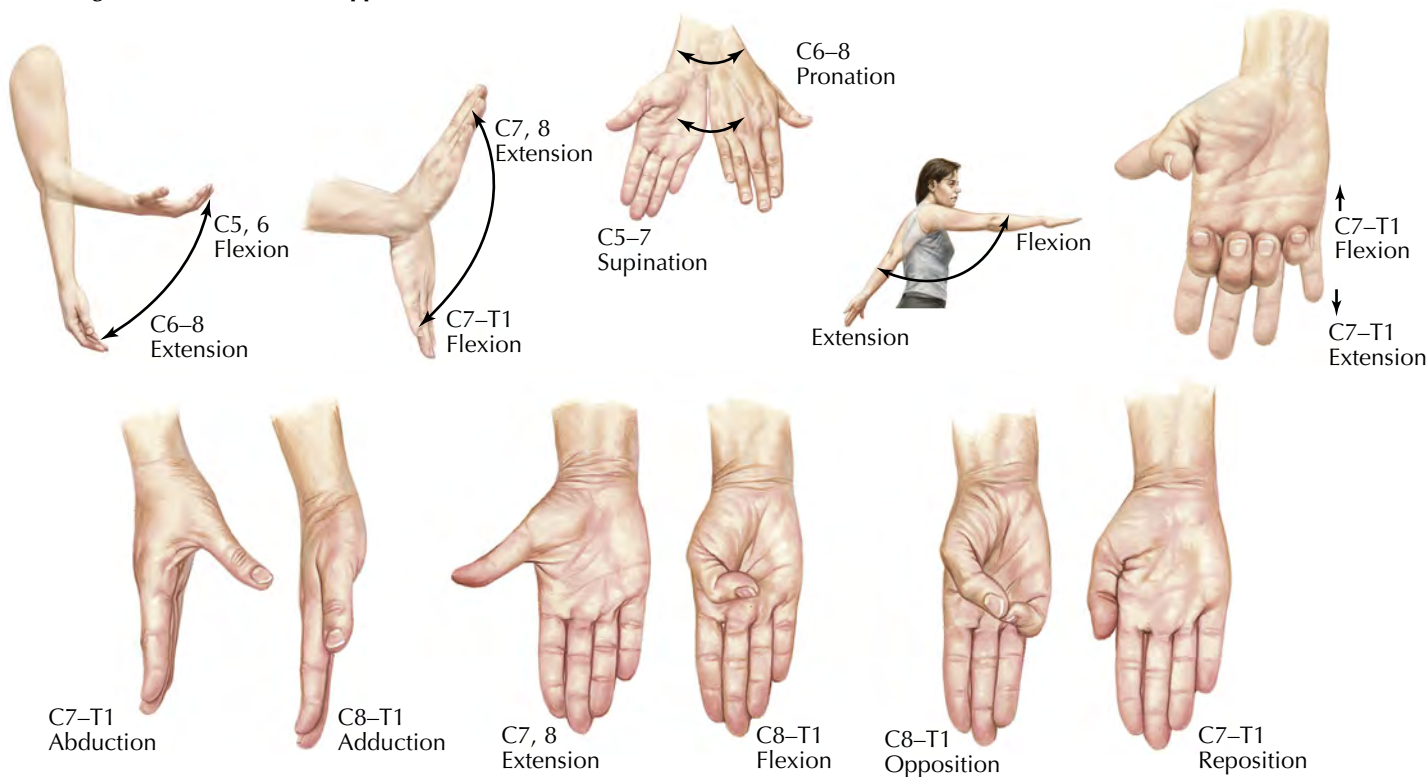


F. Plane joint (e.g., acromioclavicular joint)

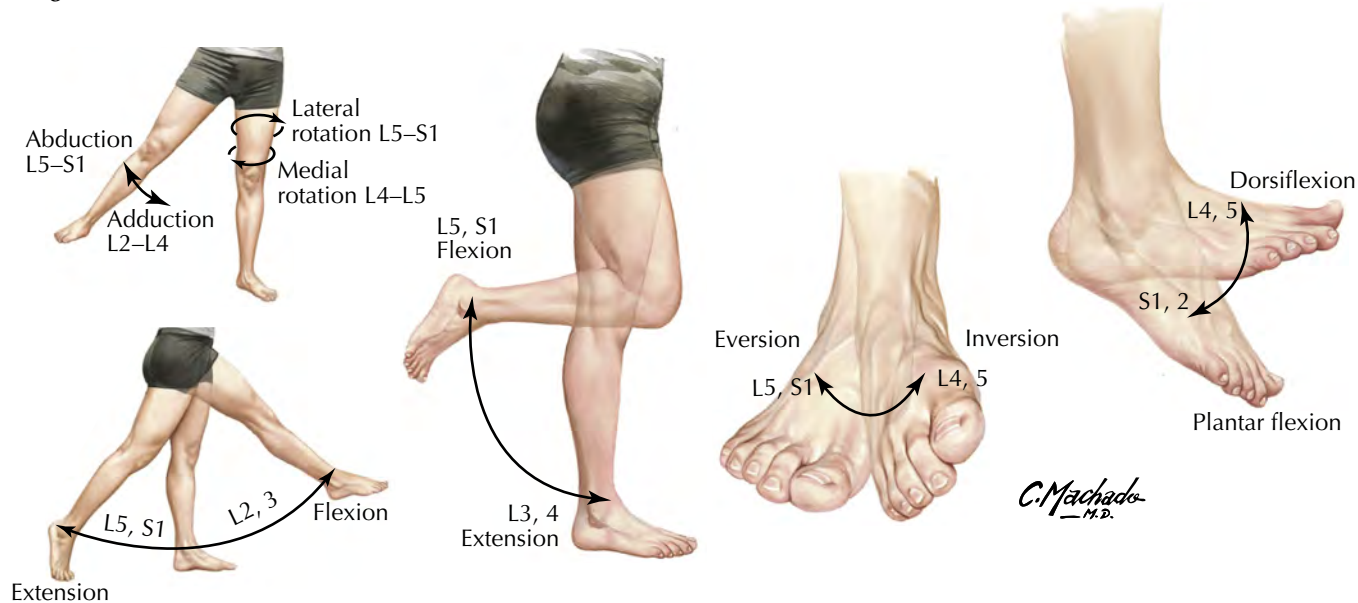
C. Machado M.D.

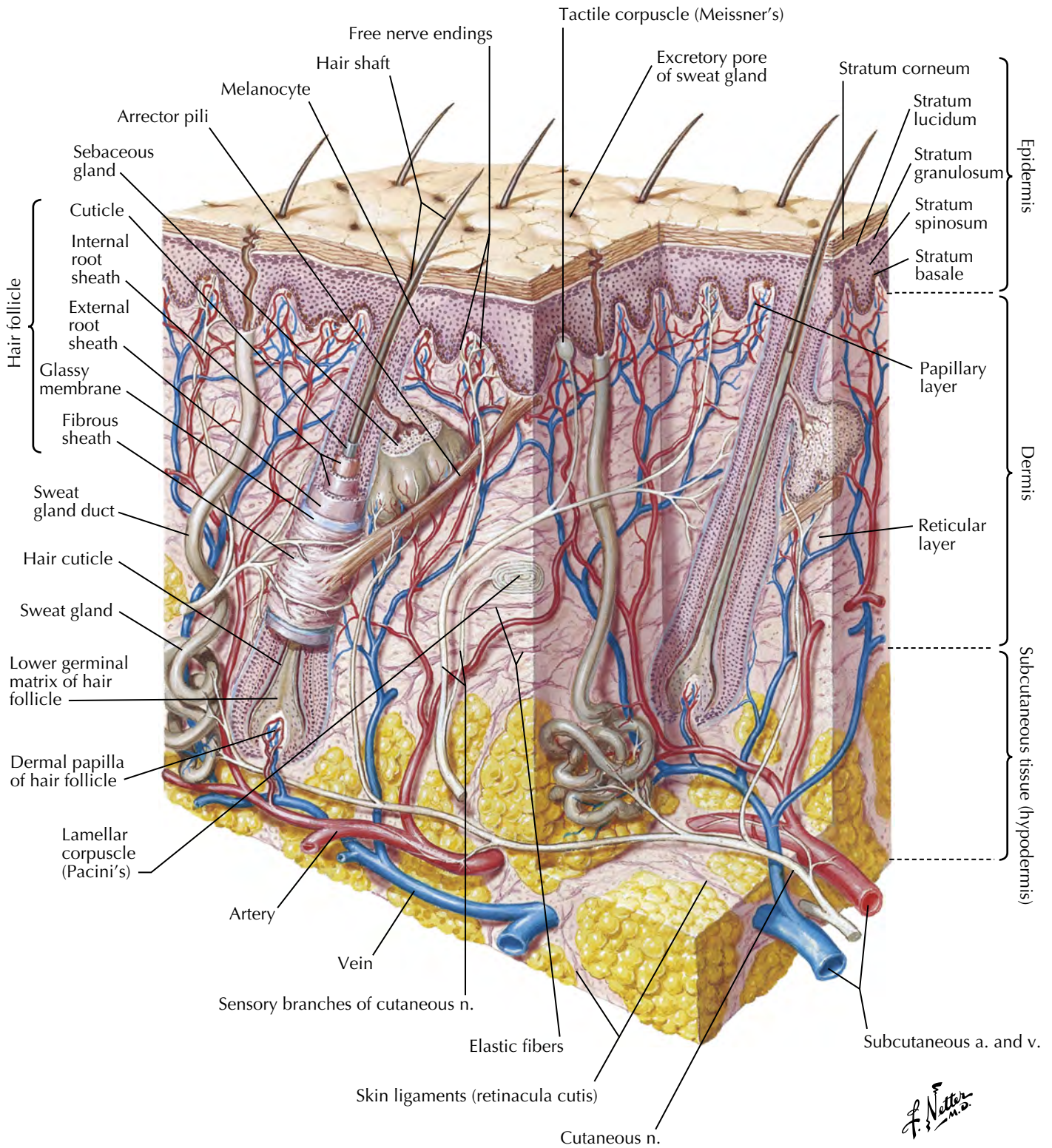


Segmental innervation of upper limb movements

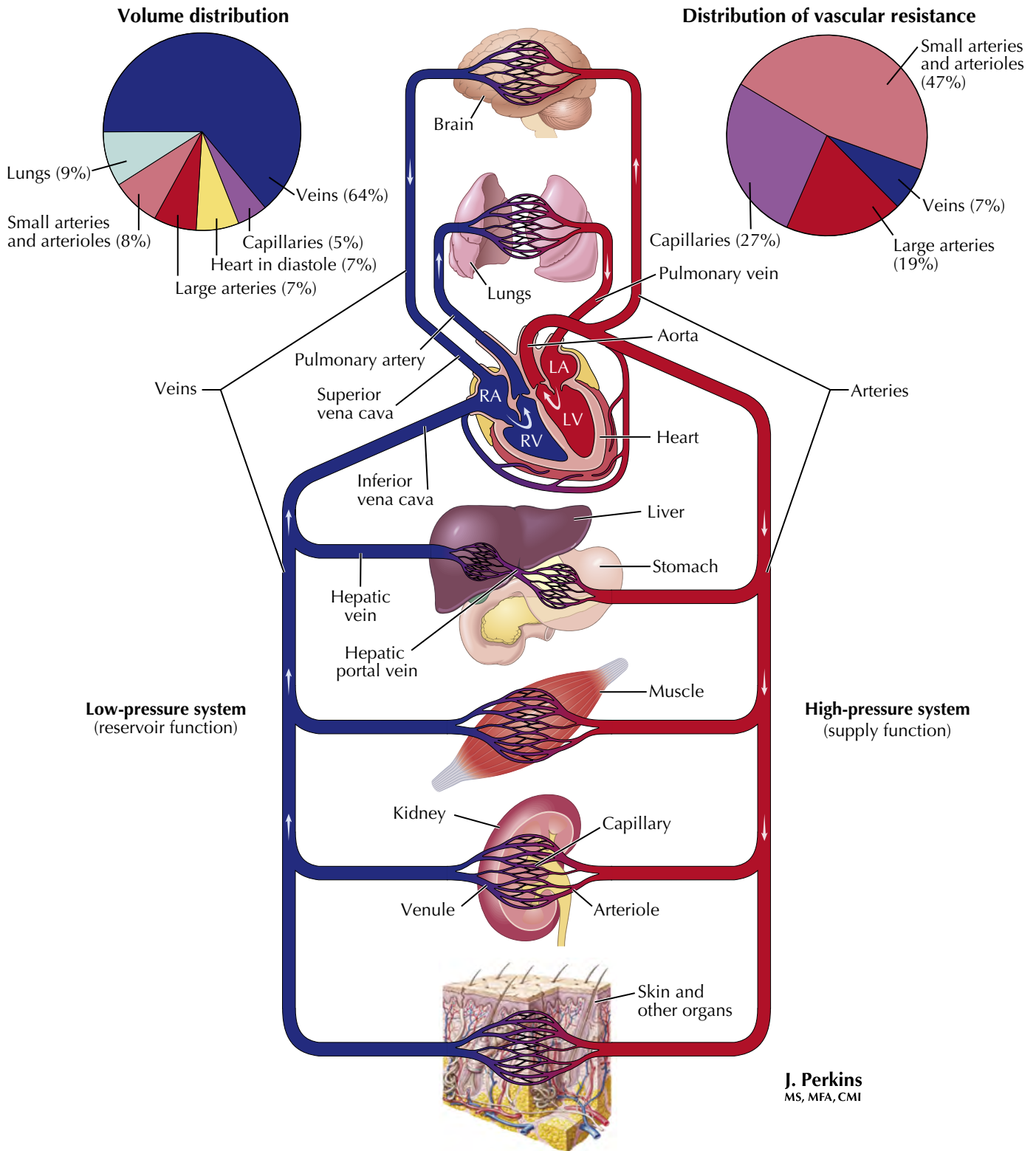


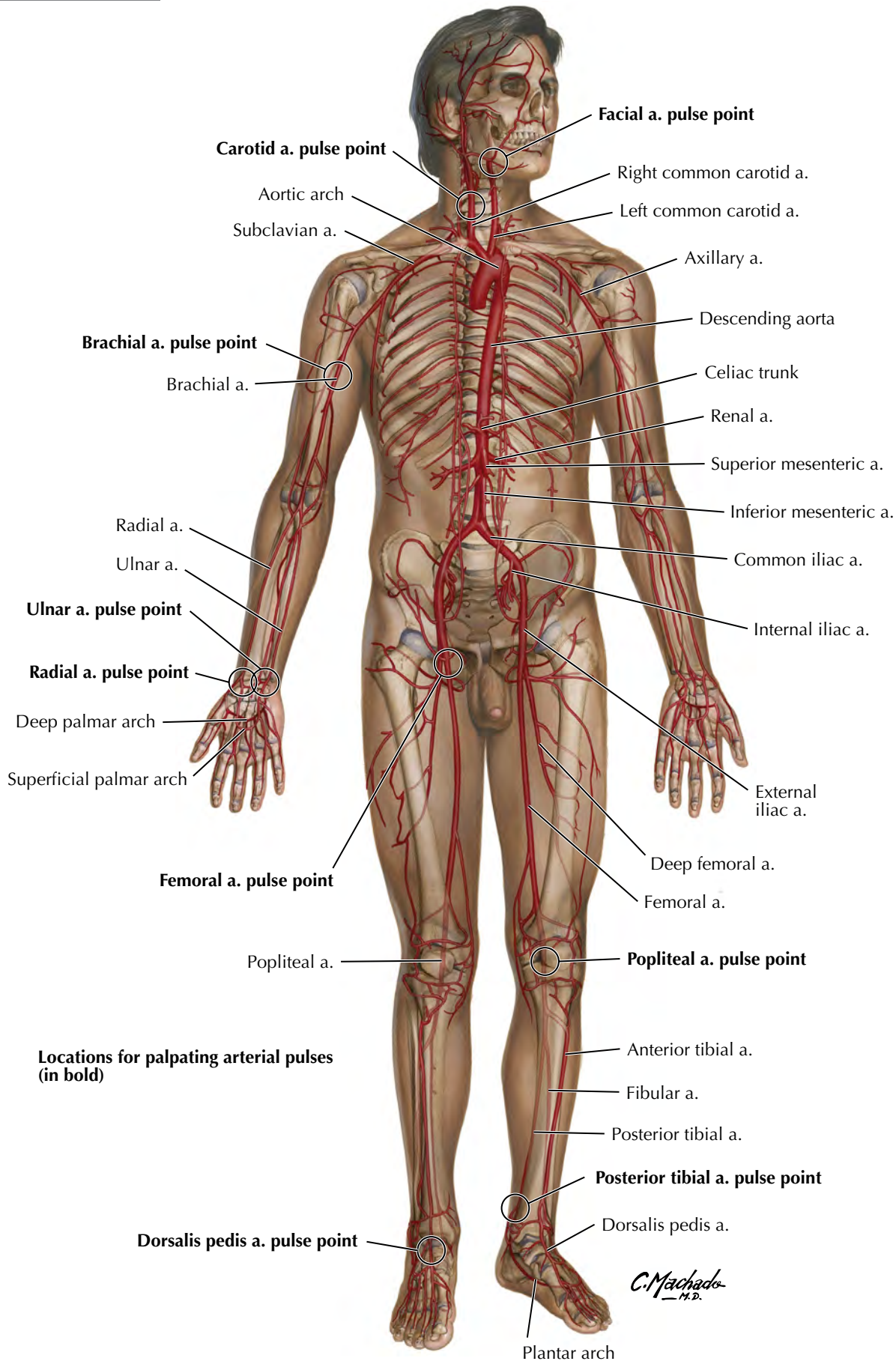
Segmental innervation of lower limb movements

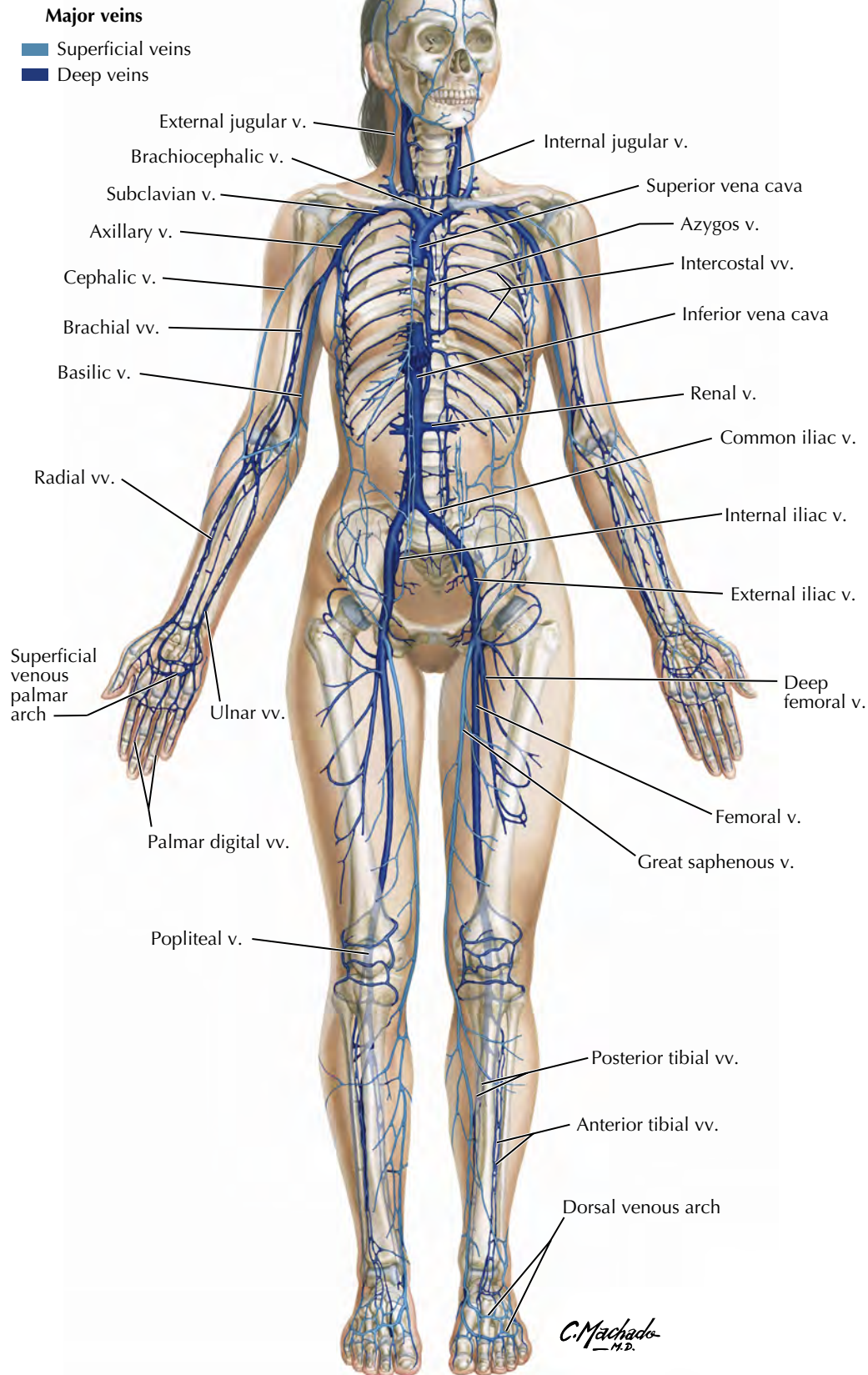




F. Netter M.D.



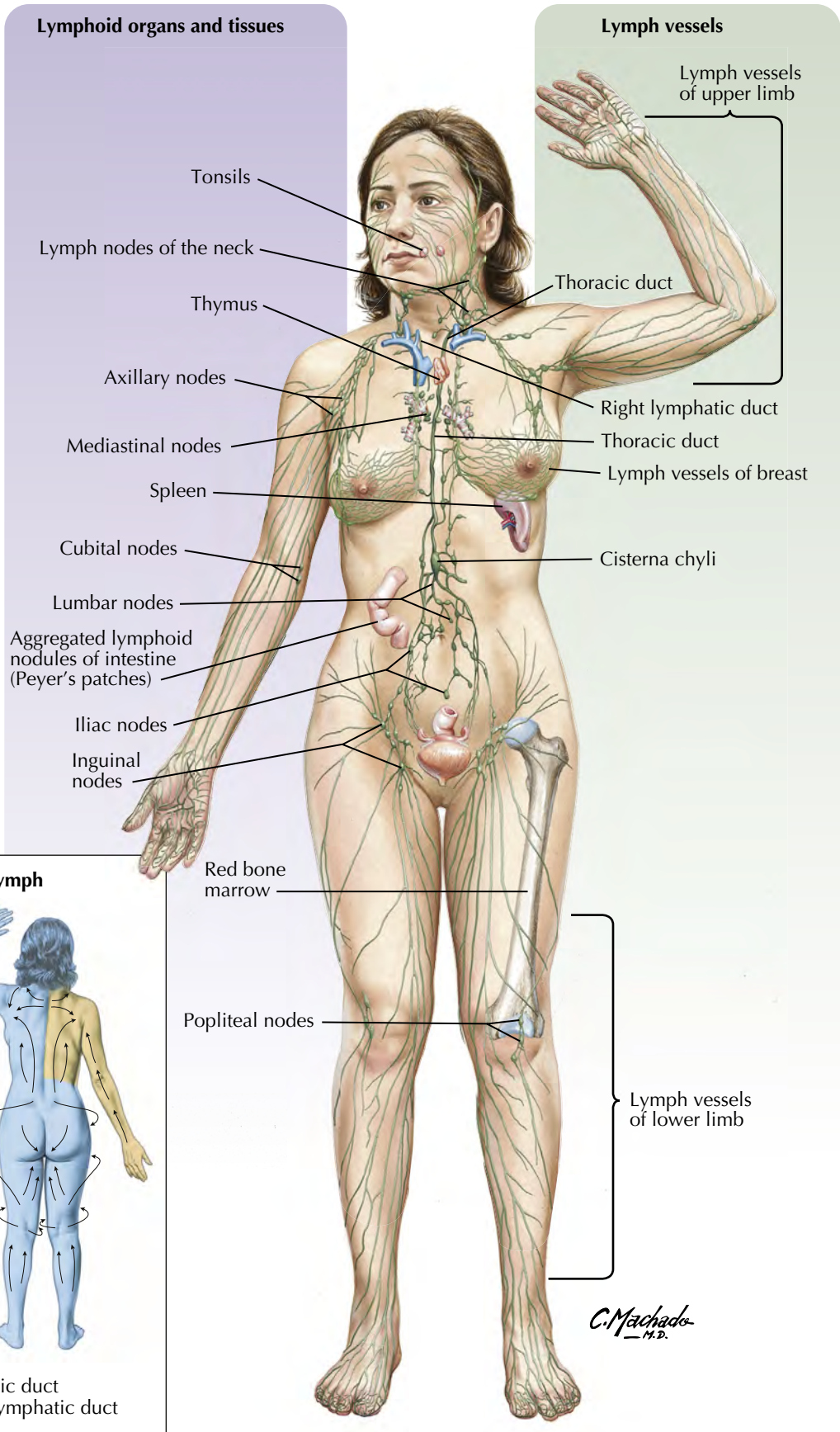




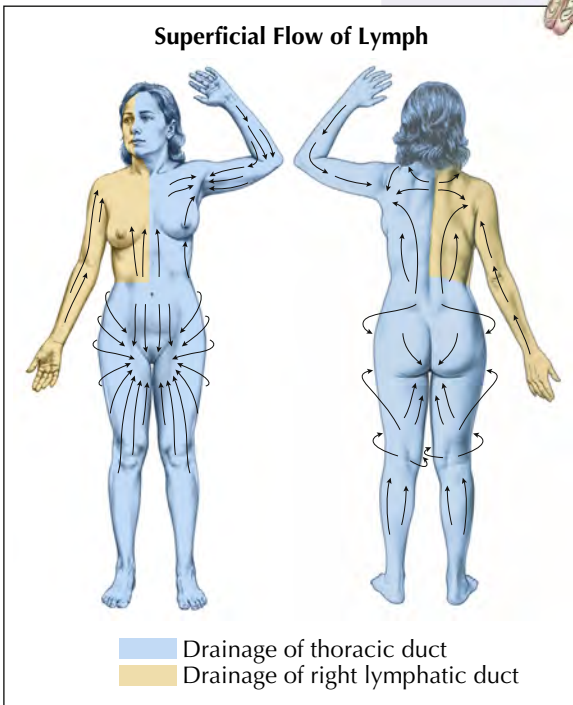
Overview of Lymph Vessels and Lymphoid Organs

Lymphoid organs and tissues

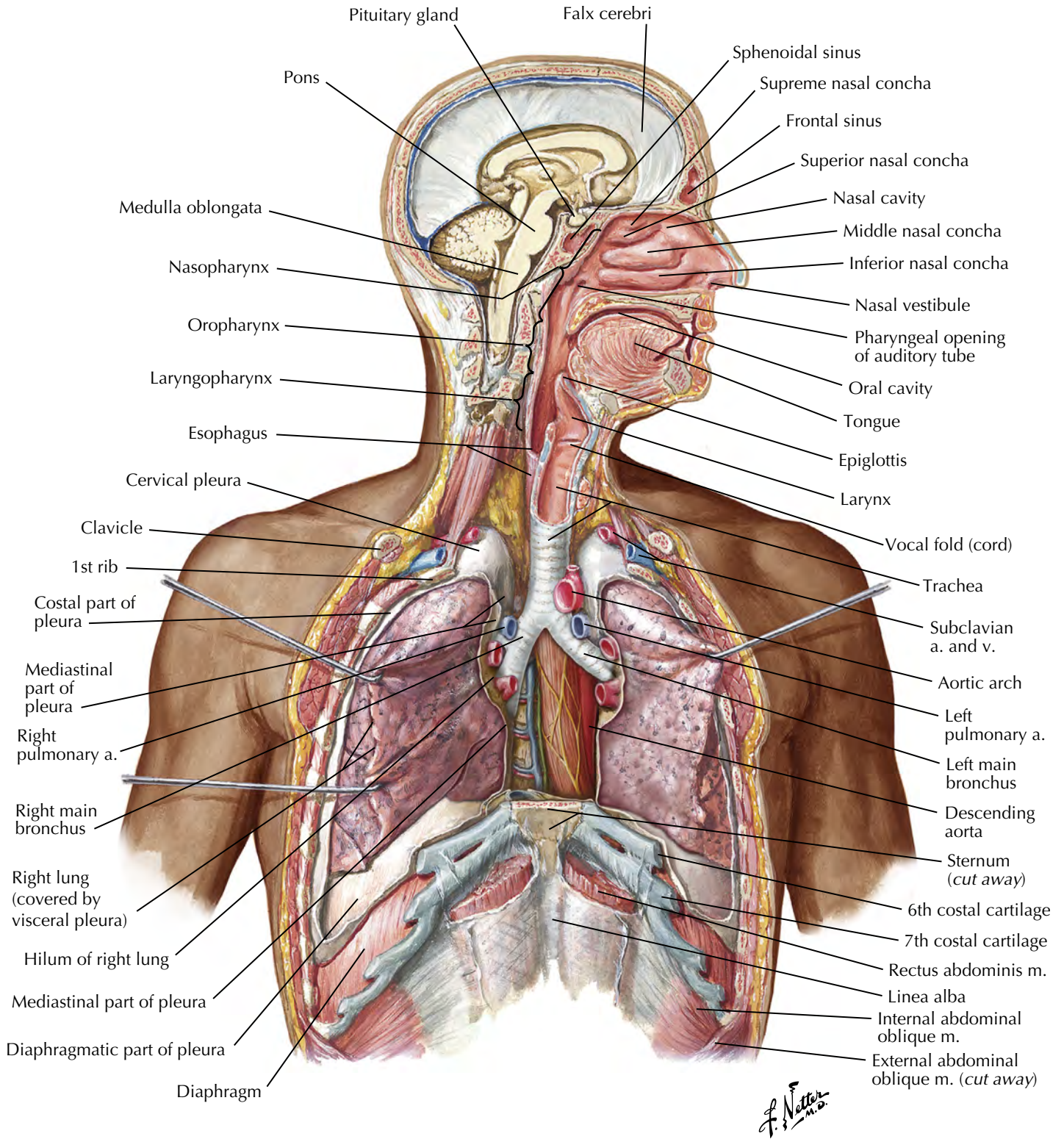
Lymph vessels



Superficial Flow of Lymph



C. Machado M.D.



Pharynx

Pharyngeal muscles propel food into esophagus

Liver

Secretion of bile (important for lipid digestion); storage of nutrients; production of cellular fuels, plasma proteins, and clotting factors; detoxification and phagocytosis

Pancreas

Secretion of buffers and digestive enzymes by exocrine cells; secretion of hormones by endocrine cells to regulate digestion

Oral cavity, teeth, tongue

Mechanical breakdown, mixing with saliva

Salivary glands (sublingual, submandibular, parotid)

Secretion of lubricating fluid containing enzymes that initiate digestion

Esophagus

Transport of food into the stomach

Gallbladder

Concentration and storage of bile

Large intestine

Dehydration and compaction of indigestible materials for elimination; resorption of water and electrolytes; host defense

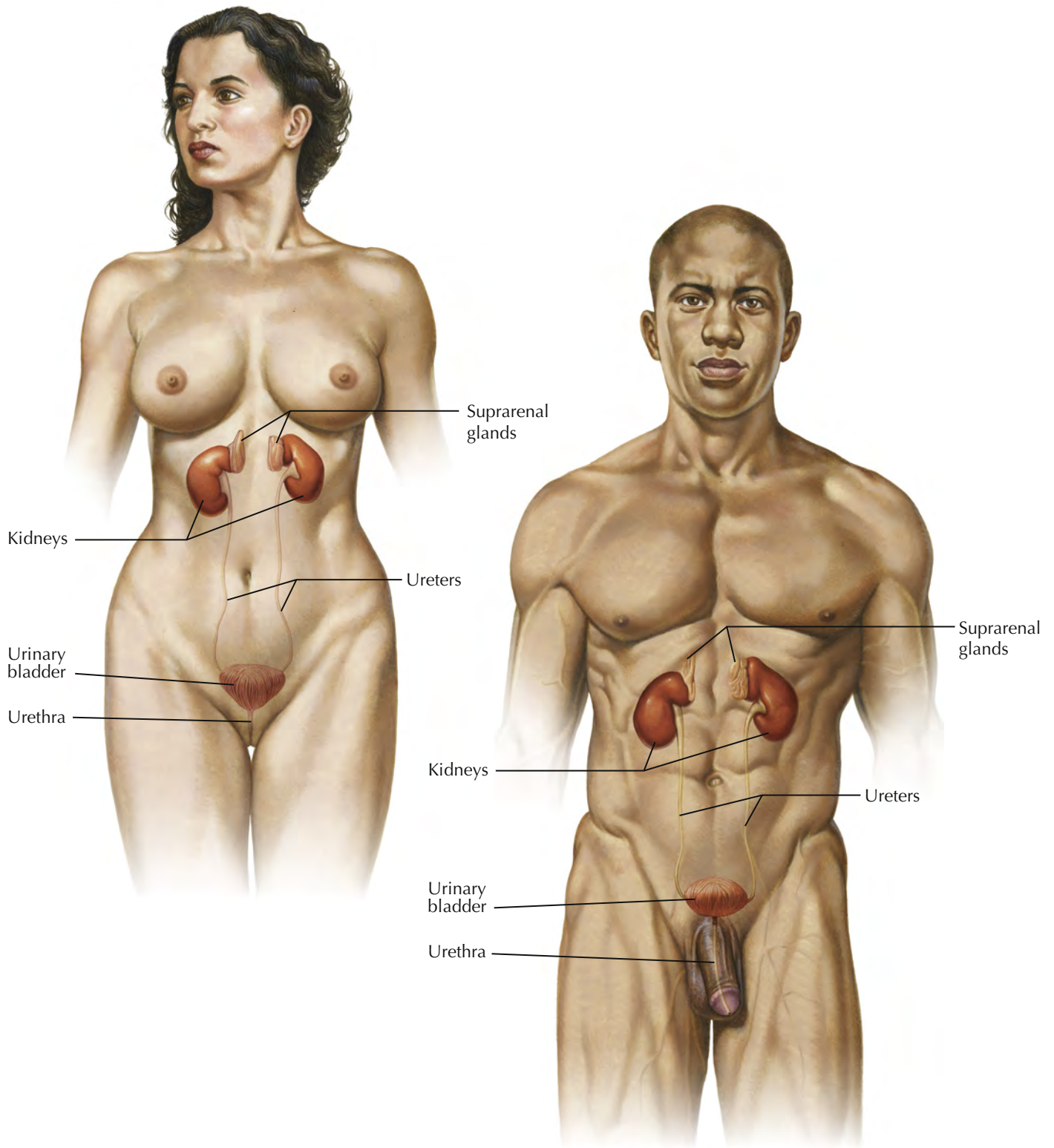
Stomach

Chemical breakdown of food by acid and enzymes; mechanical breakdown via muscular contractions; absorption of water, alcohol, and some minerals

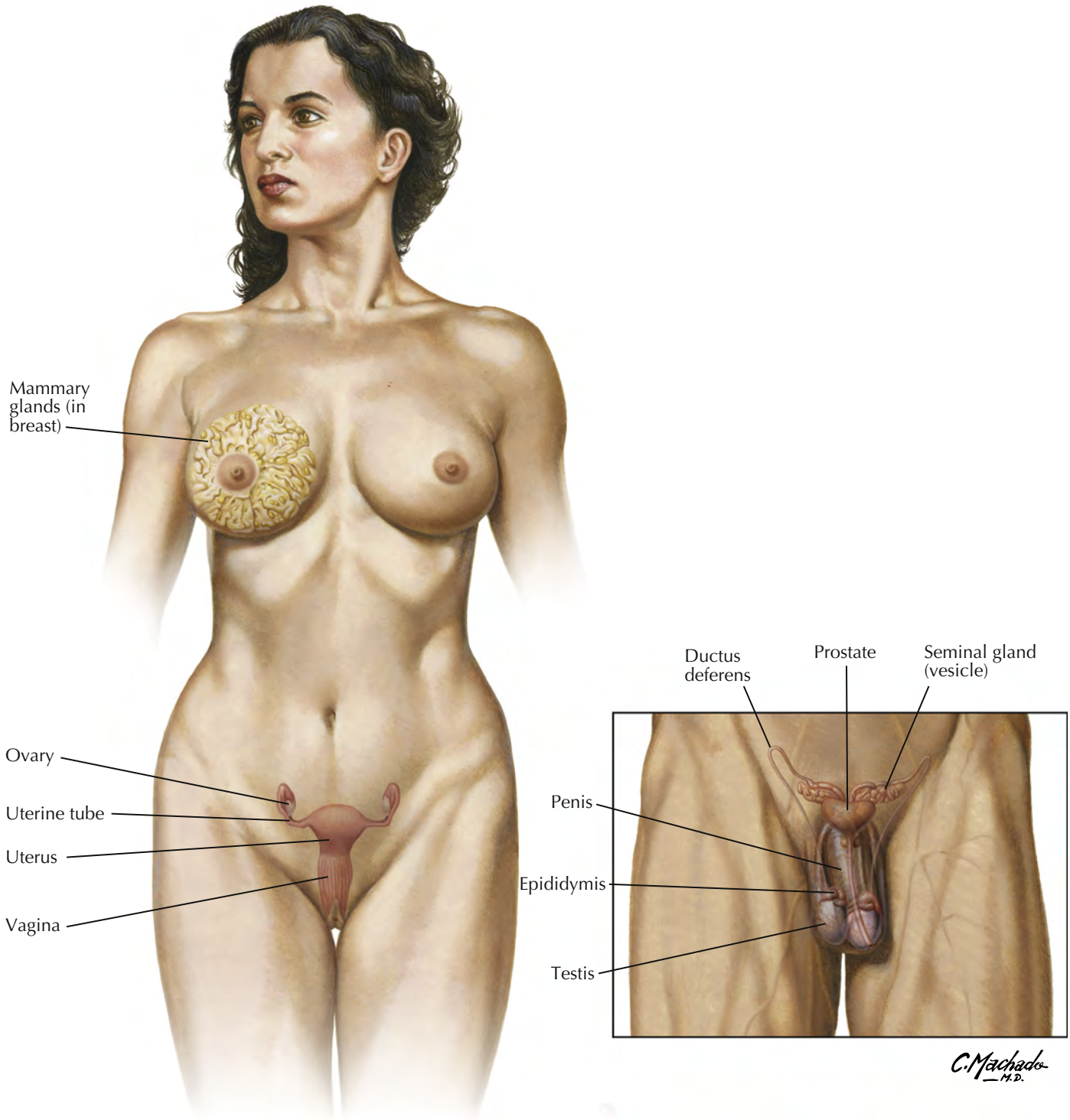
Small intestine

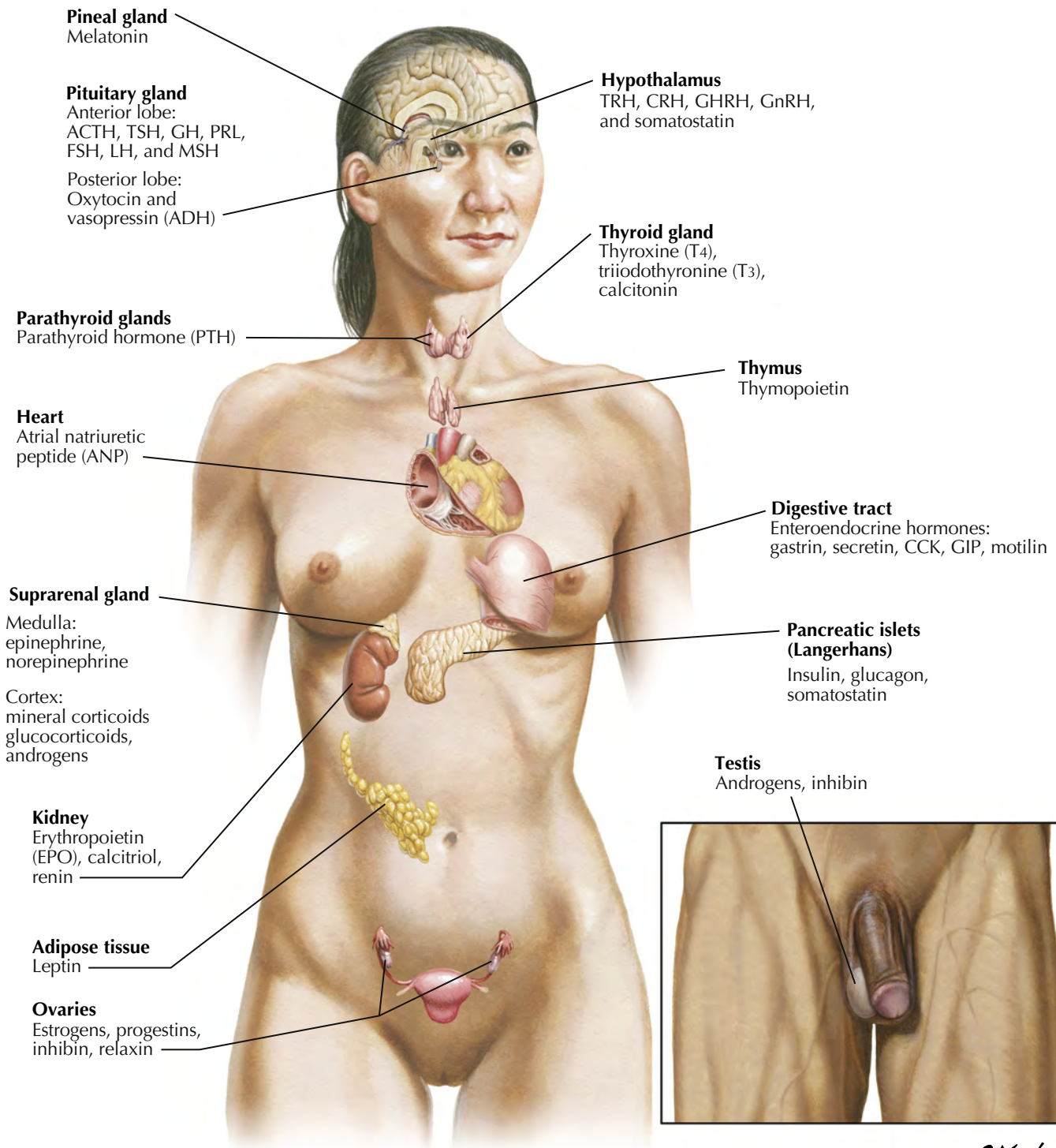
Neutralization of acid from stomach; enzymatic digestion and absorption of water, organic substrates, vitamins, and ions; host defense

C. Machado
M.D.

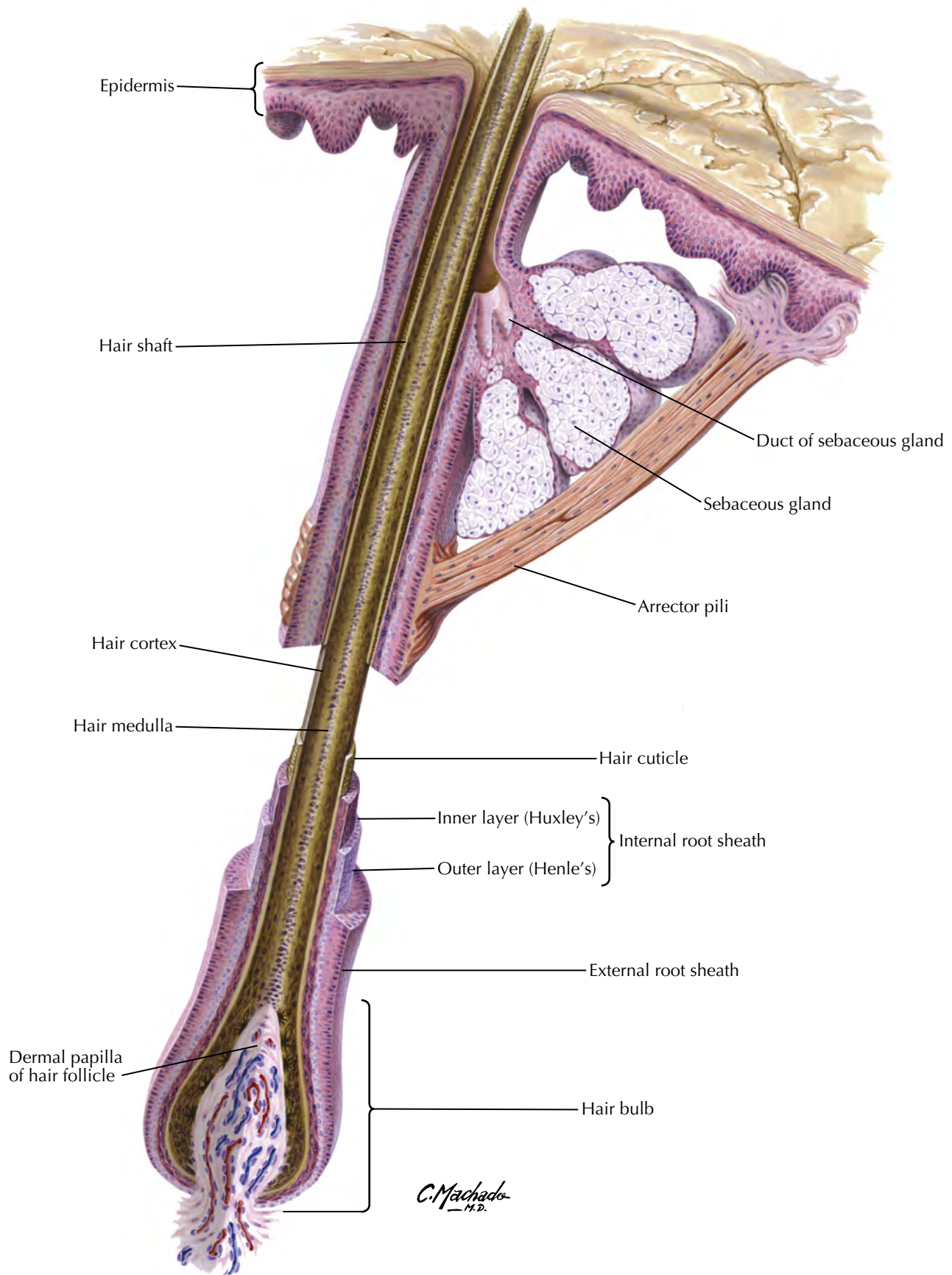


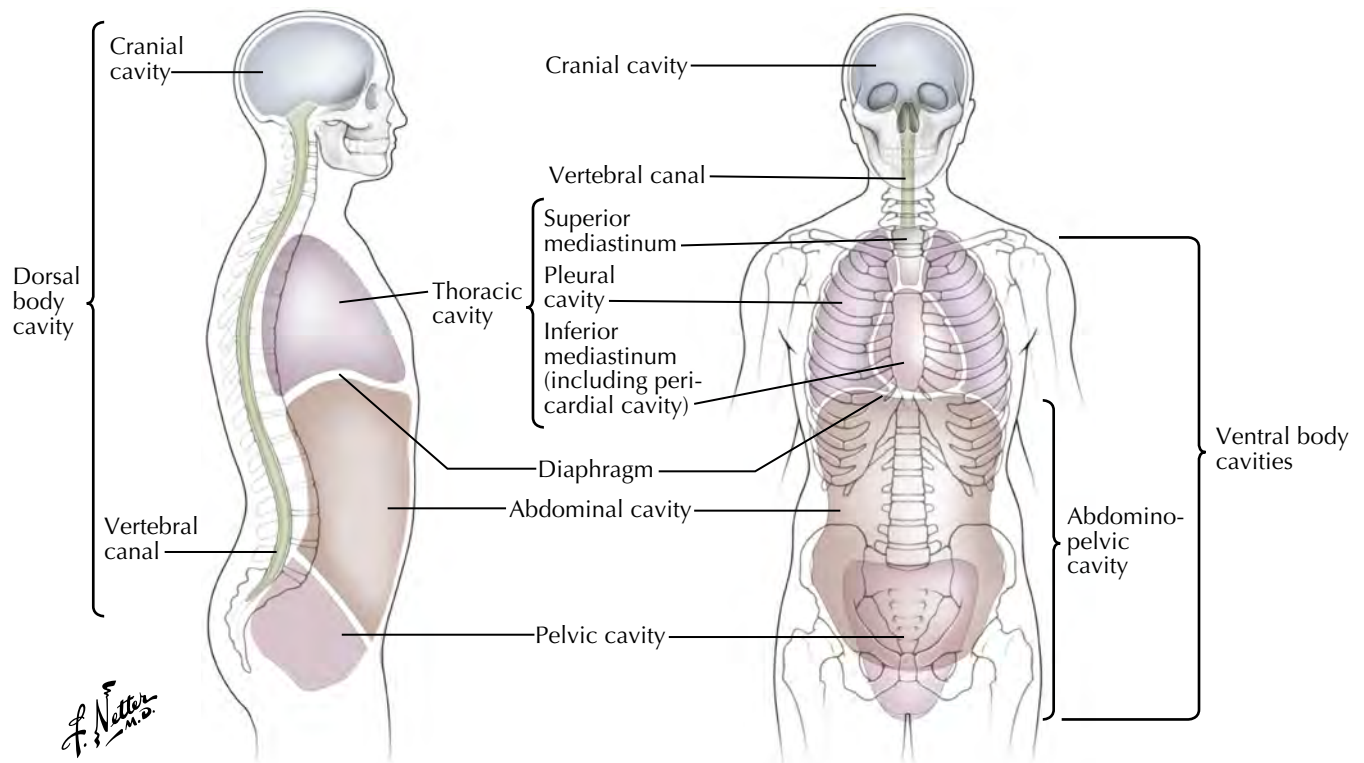
C. Machado
—M.D.





C. Machado
—M.D.

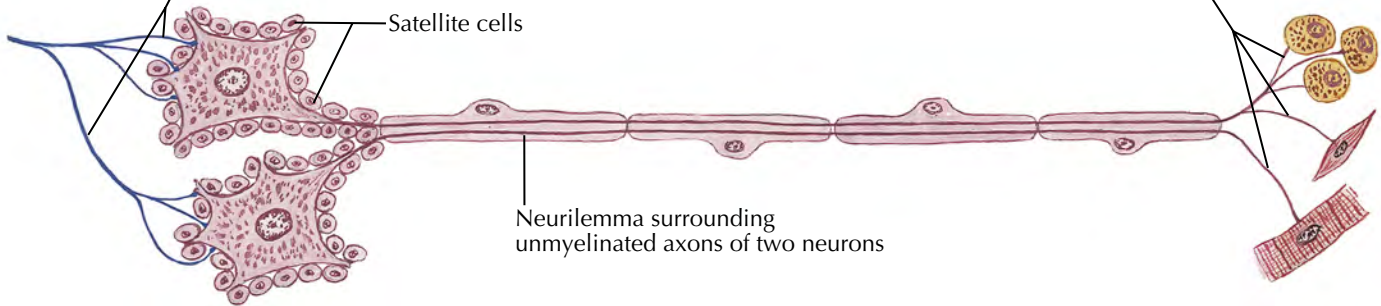




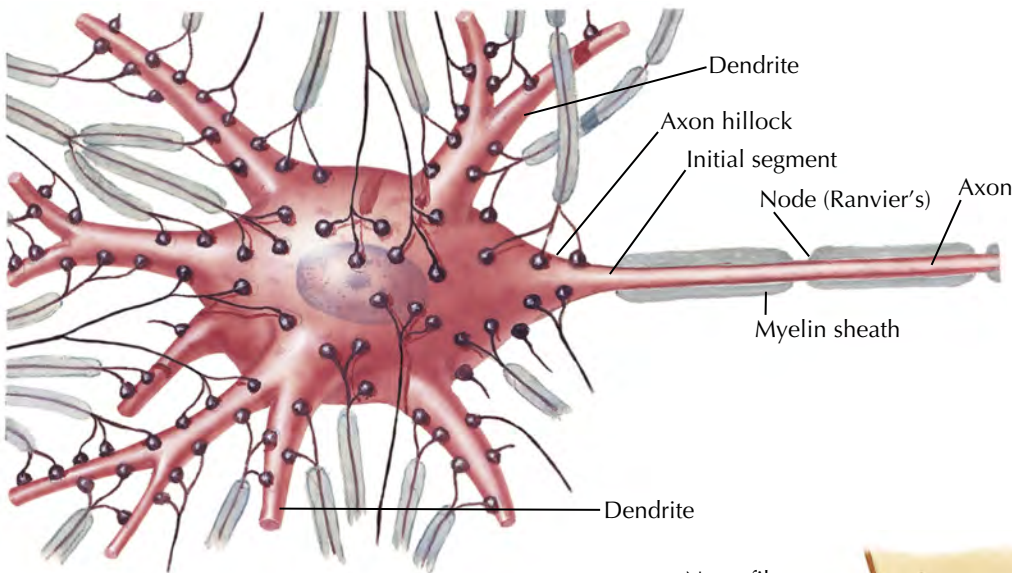
See also Plate BP 4

Endings of autonomic preganglionic fiber synapsing onto cell bodies of ganglionic neurons

Autonomic nerve endings on glandular epithelium, or smooth or cardiac muscle cells

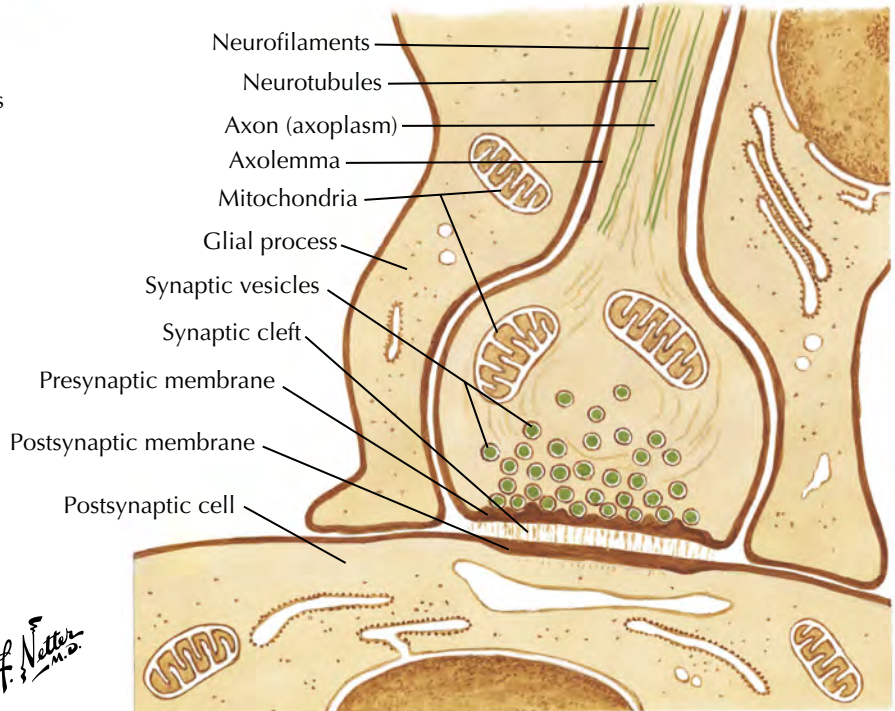


Two postganglionic autonomic neurons of a sympathetic or parasympathetic ganglion

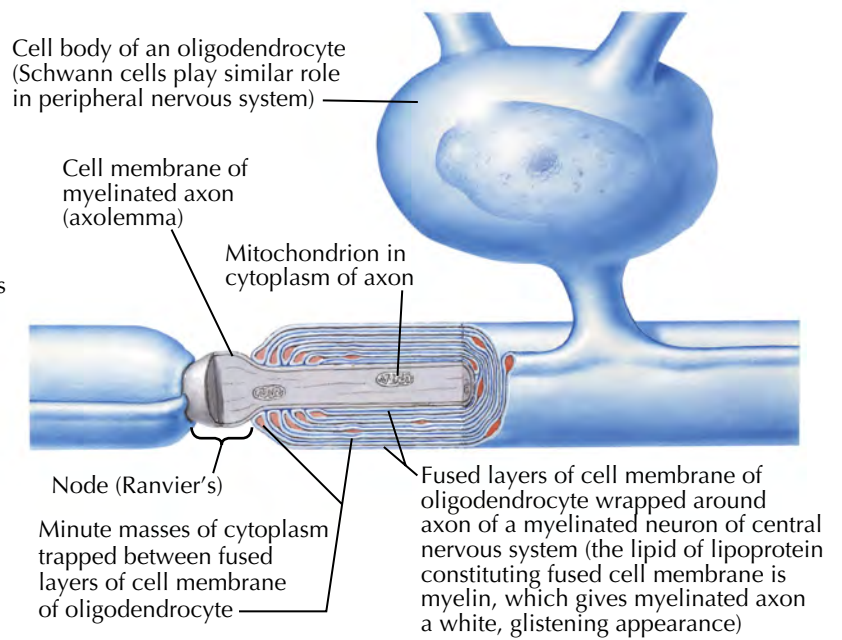
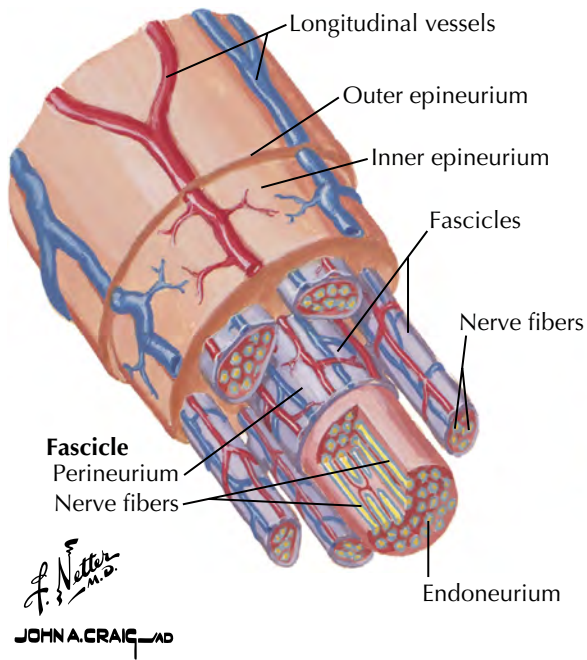


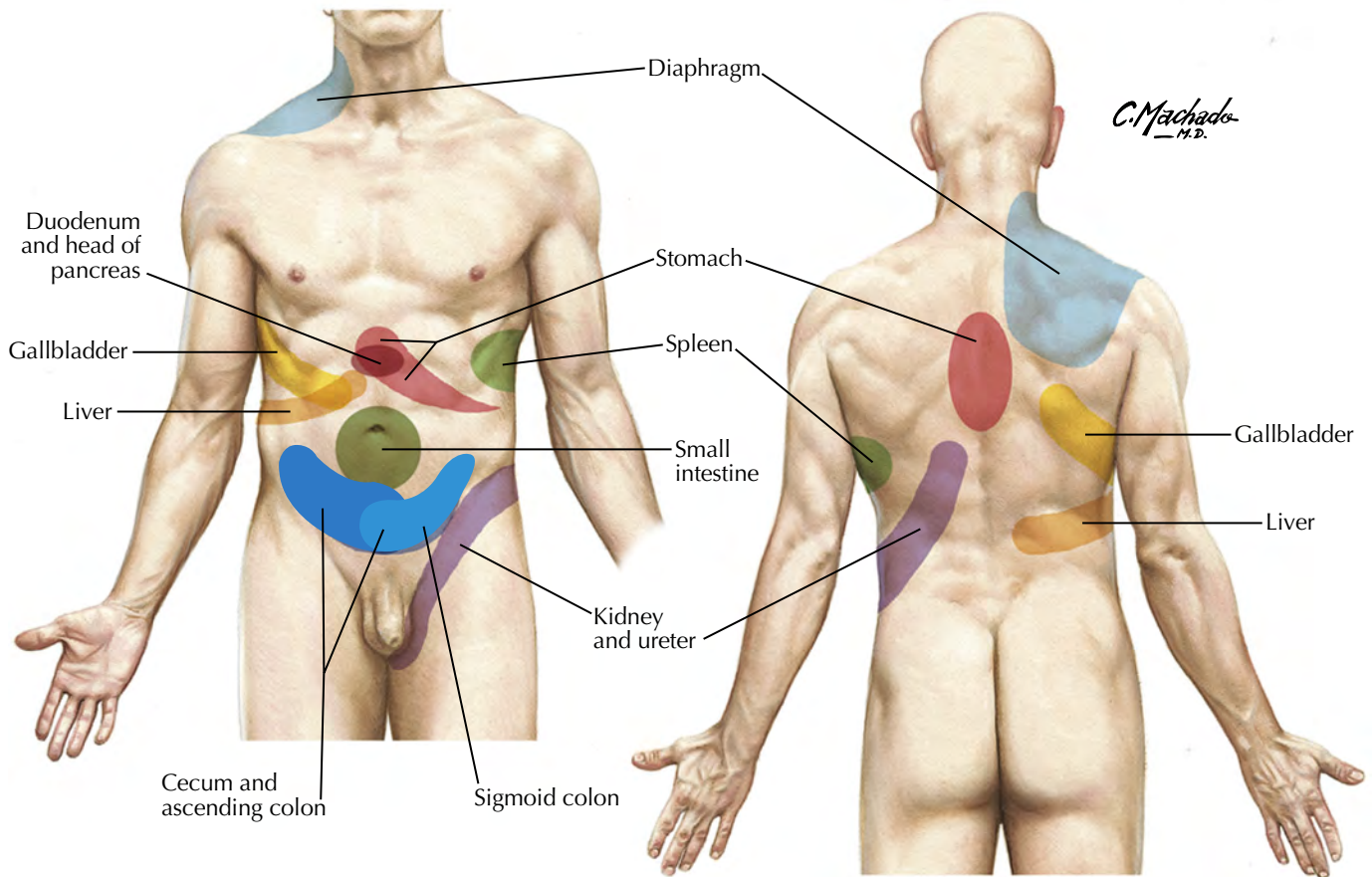
Schematic of synapses on neuron

Numerous terminal boutons forming synapses on body and dendrites of a motor neuron

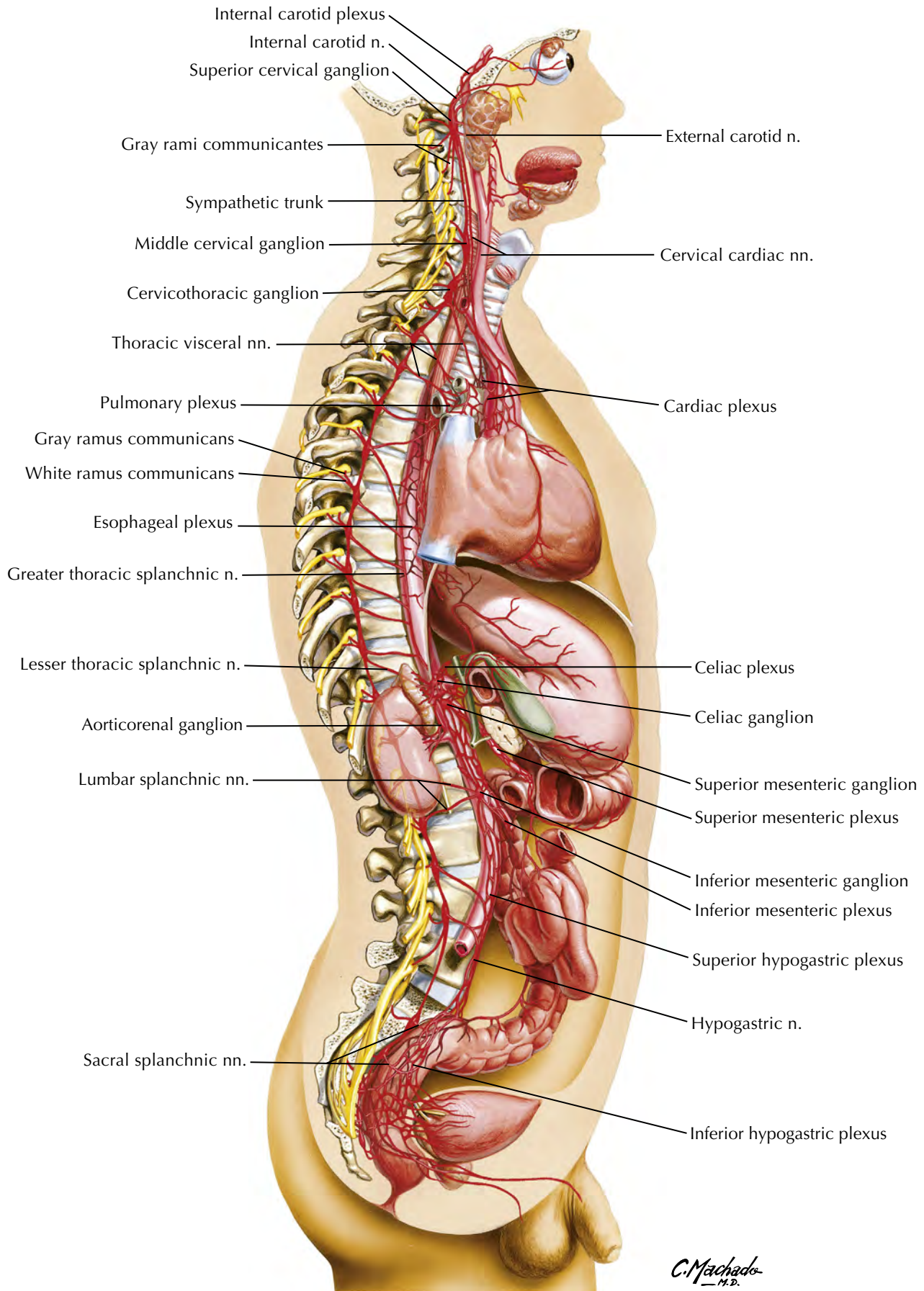


Enlarged section of bouton

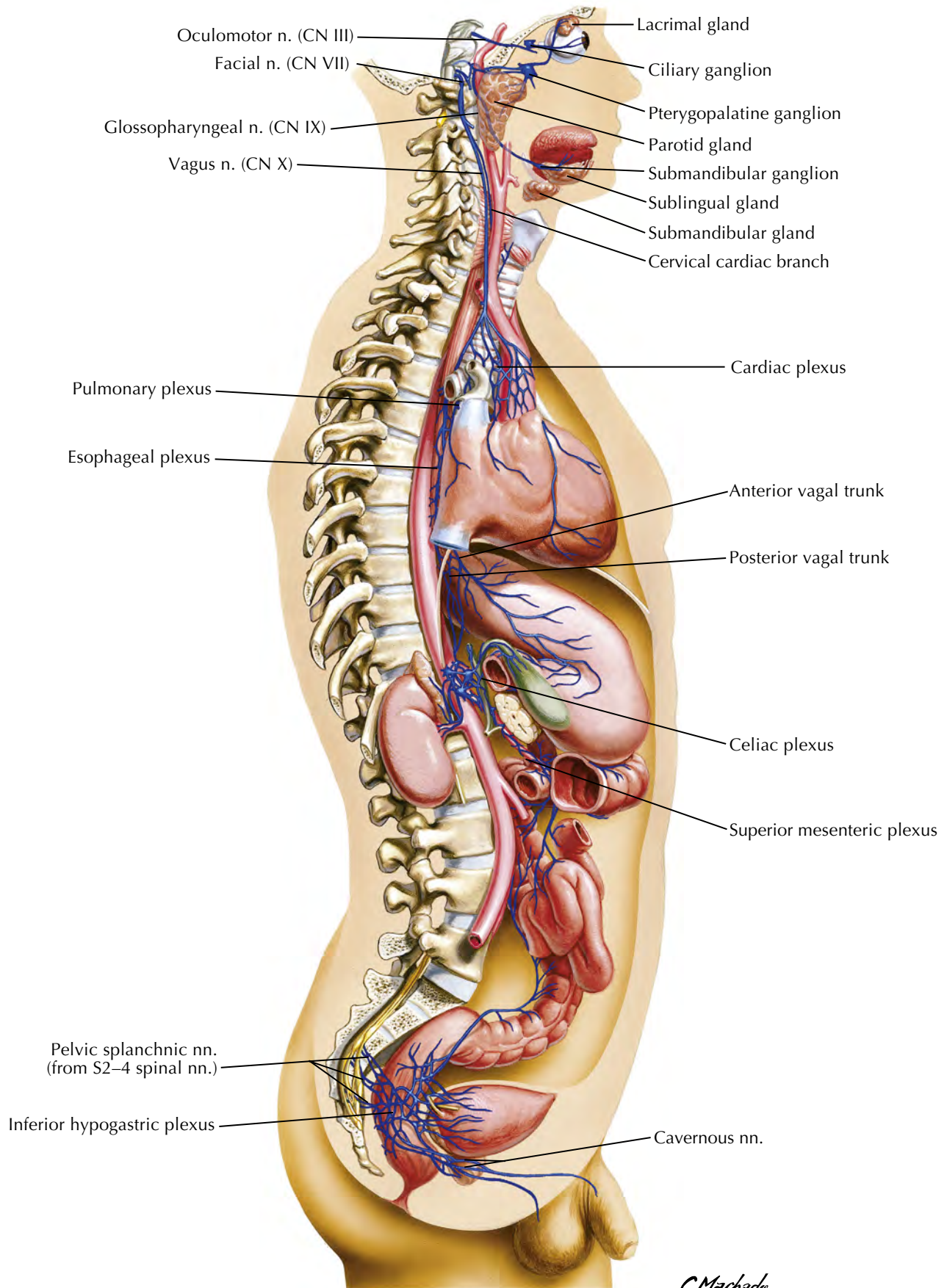




Sympathetic Nervous System: General Topography

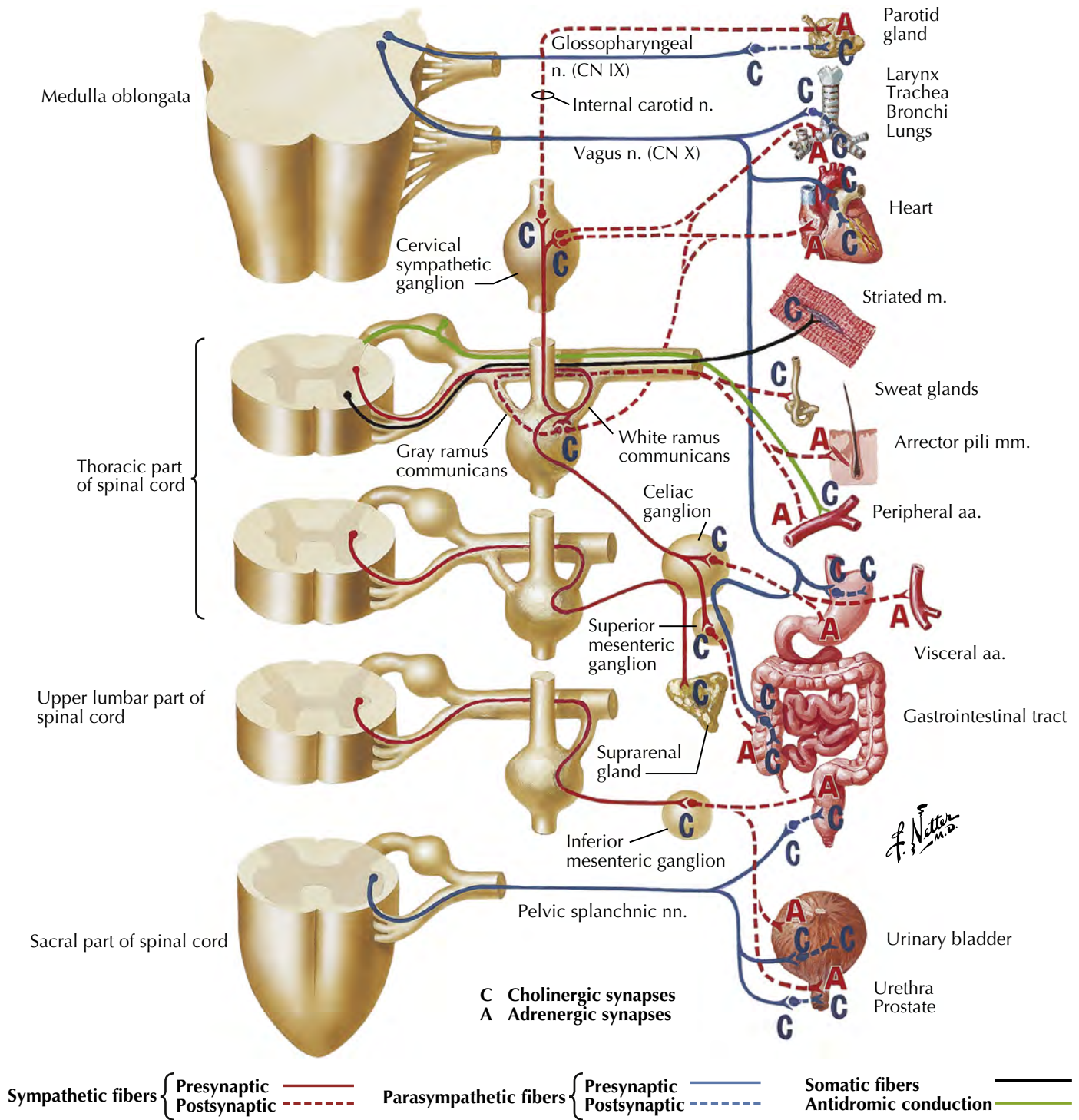


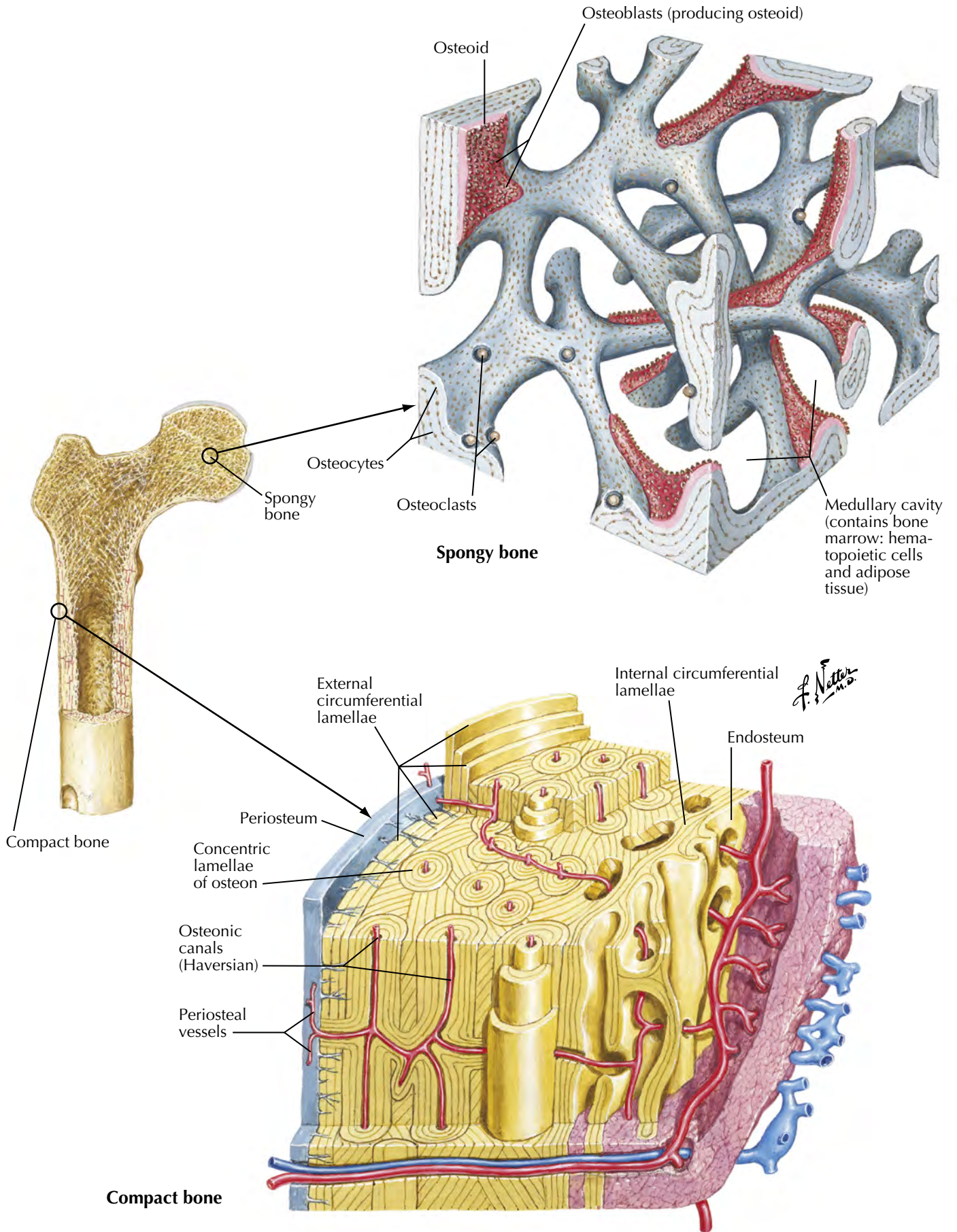
C. Machado
M.D.

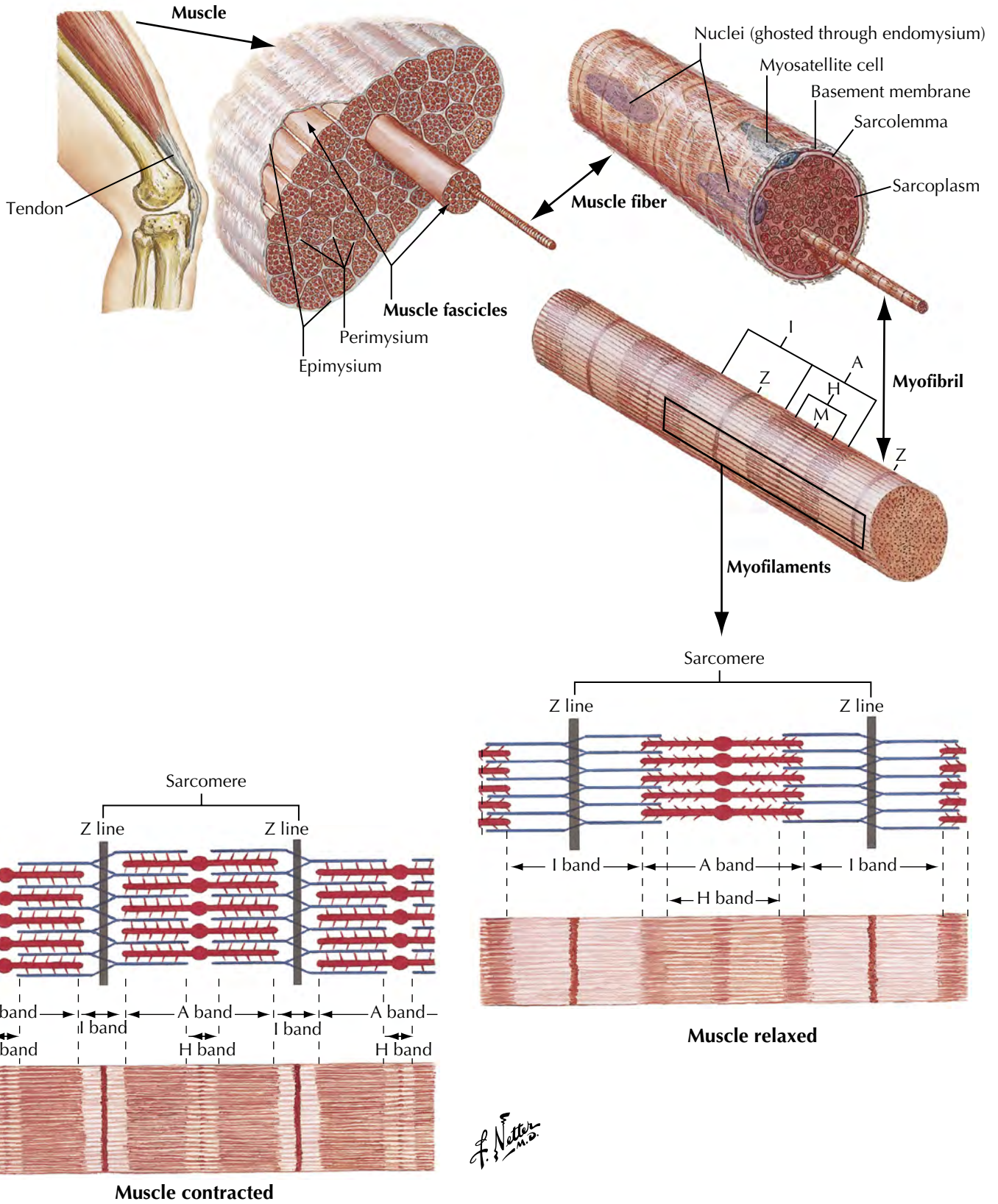


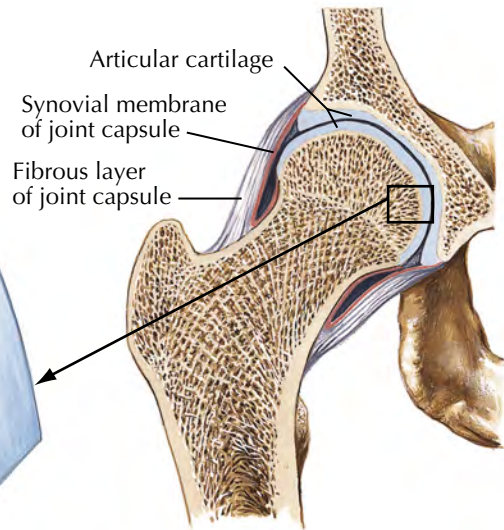
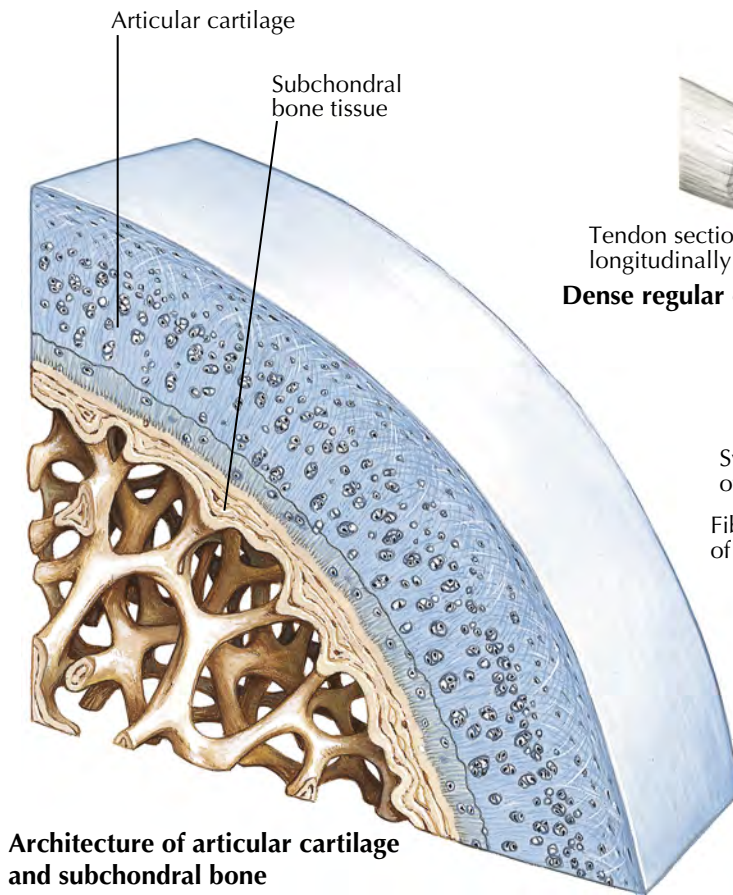
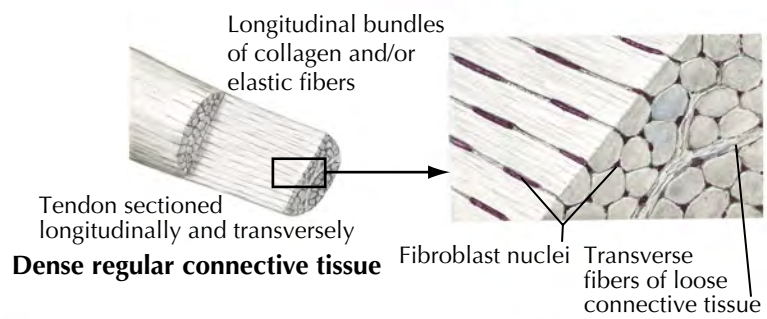
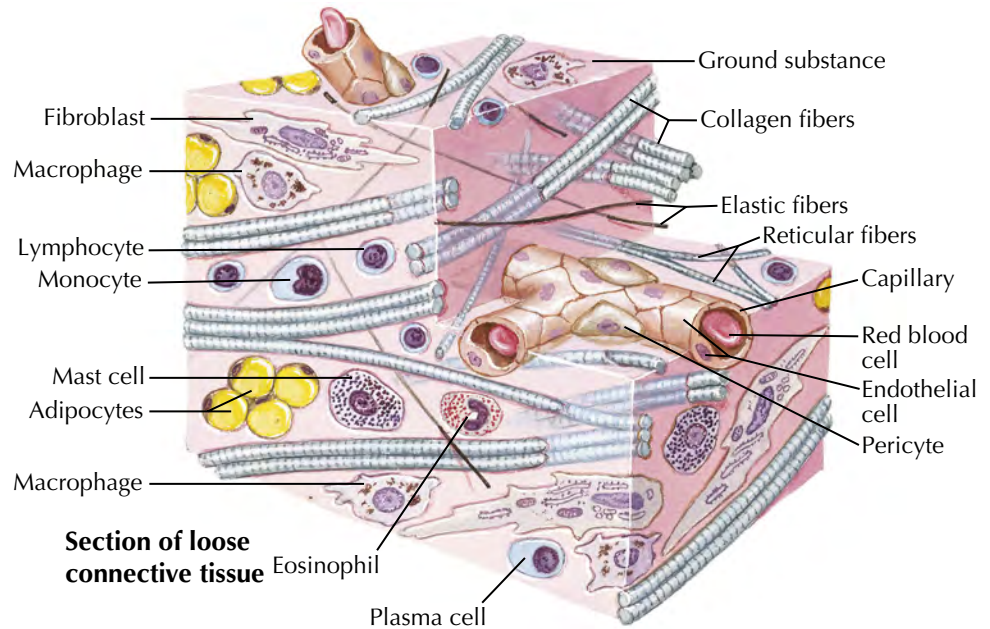
C. Machado
—M.D.

Cholinergic and Adrenergic Synapses: Schema

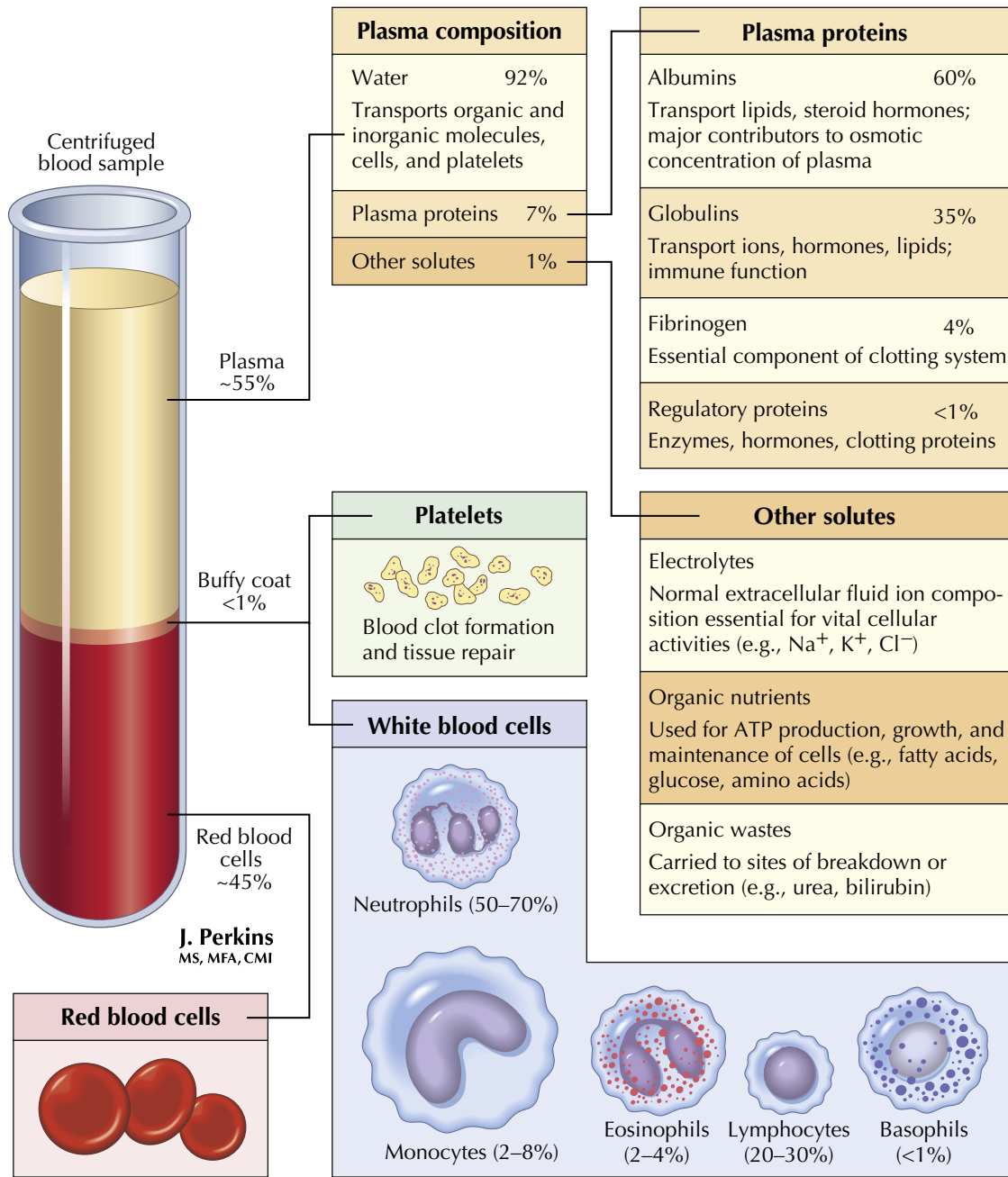


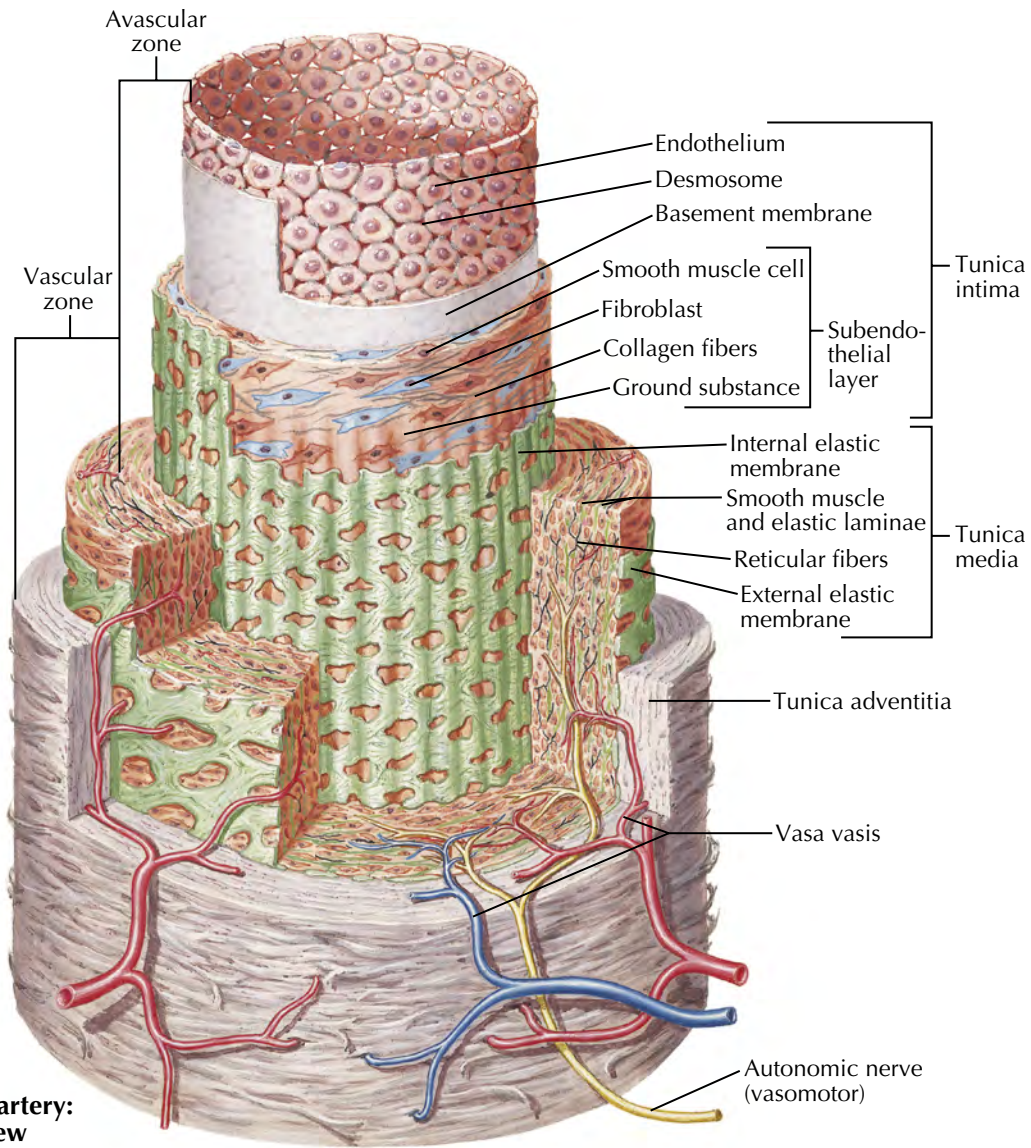




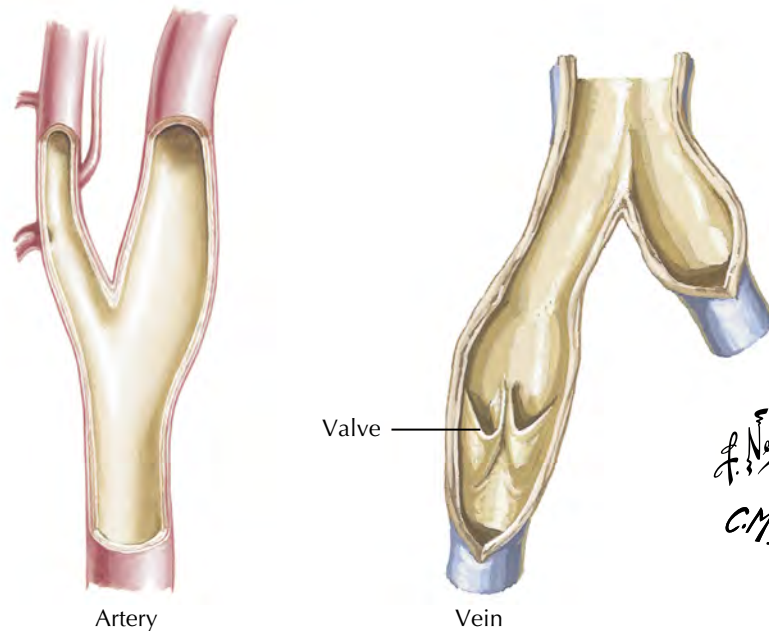


F. Netter M.D.
C. Machado M.D.





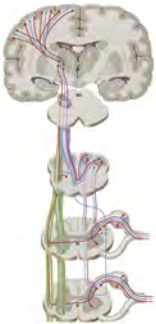Wall of an artery: cutaway view



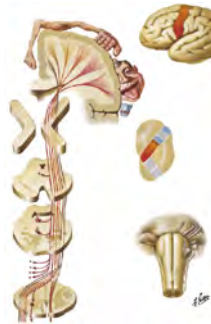HEAD AND NECK 2

Surface Anatomy	22–24	Cranial and Cervical Nerves	143–162
Bones and Joints	25–47	Cerebral Vasculature	163–175
Neck	48–58	Regional Imaging	176–177
Nose	59–82	Structures with High Clinical Significance	Tables 2.1–2.4
Mouth	83–90	Cranial Nerves	Tables 2.5–2.8
Pharynx	91–102	Branches of Cervical Plexus	Table 2.9
Larynx and Endocrine Glands	103–109	Muscles	Tables 2.10–2.14
Eye	110–120	Electronic Bonus Plates	BP 14–BP 32
Ear	121–126		
Brain and Meninges	127–142		

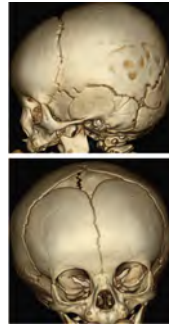
ELECTRONIC BONUS PLATES



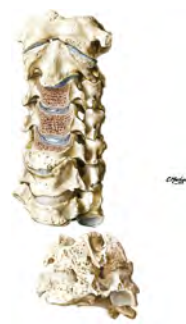BP 14 Somatosensory System: Trunk and Limbs



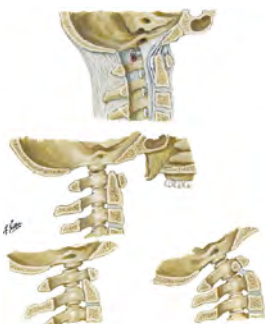BP 15 Pyramidal System



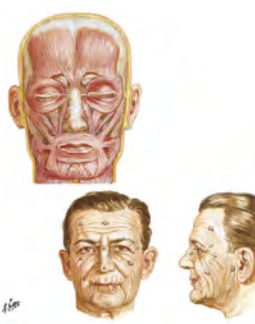BP 16 3D Skull Reconstruction CTs



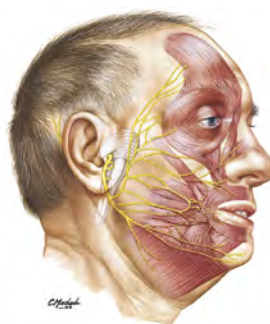BP 17 Degenerative Changes in Cervical Vertebrae



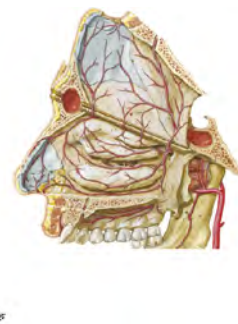
BP 18 Atlantooccipital Junction



BP 19 Muscles of Facial Expression: Anterior View

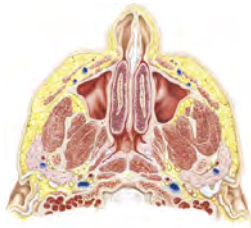

BP 20 Musculature of Face

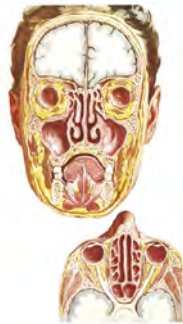


BP 21 Arteries of Nasal Cavity: Bony Nasal Septum Turned Up

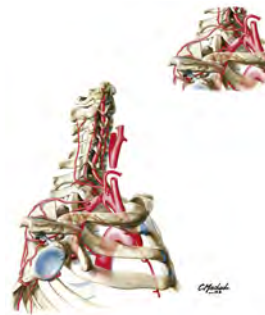ELECTRONIC BONUS PLATES—*cont'd*



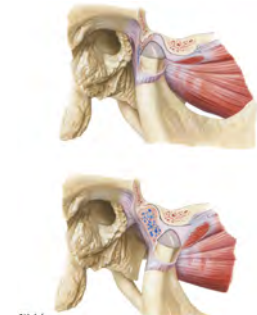
BP 22 Nose and Maxillary Sinus: Transverse Section



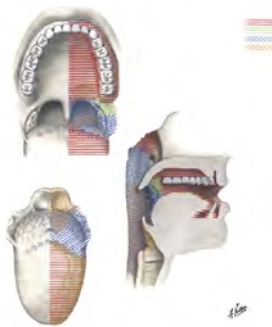
BP 23 Paranasal Sinuses



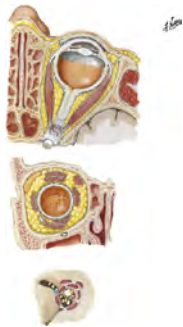BP 24 Subclavian Artery



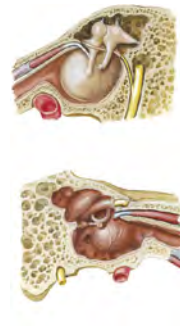
BP 25 Opening of the Mandible



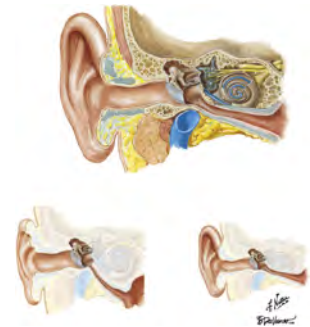BP 26 Afferent Innervation of Oral Cavity and Pharynx



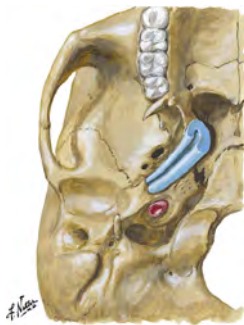BP 27 Fasciae of Orbit and Eyeball



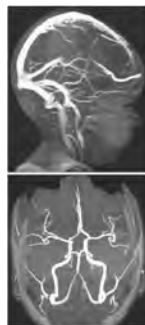BP 28 Tympanic Cavity: Medial and Lateral Views



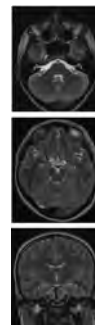
BP 29 Anatomy of the Pediatric Ear



BP 30 Auditory Tube (Eustachian)

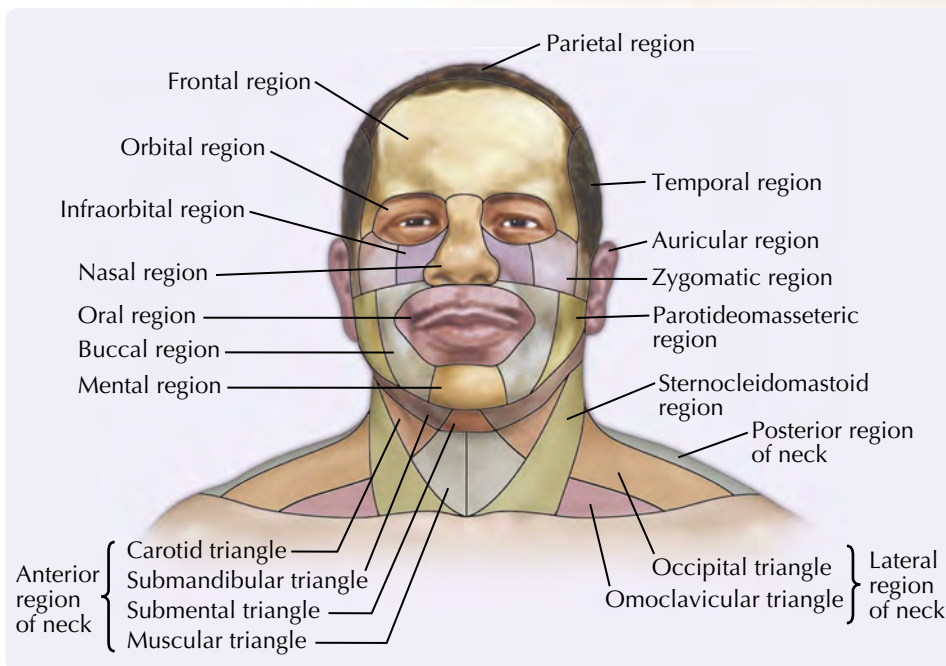
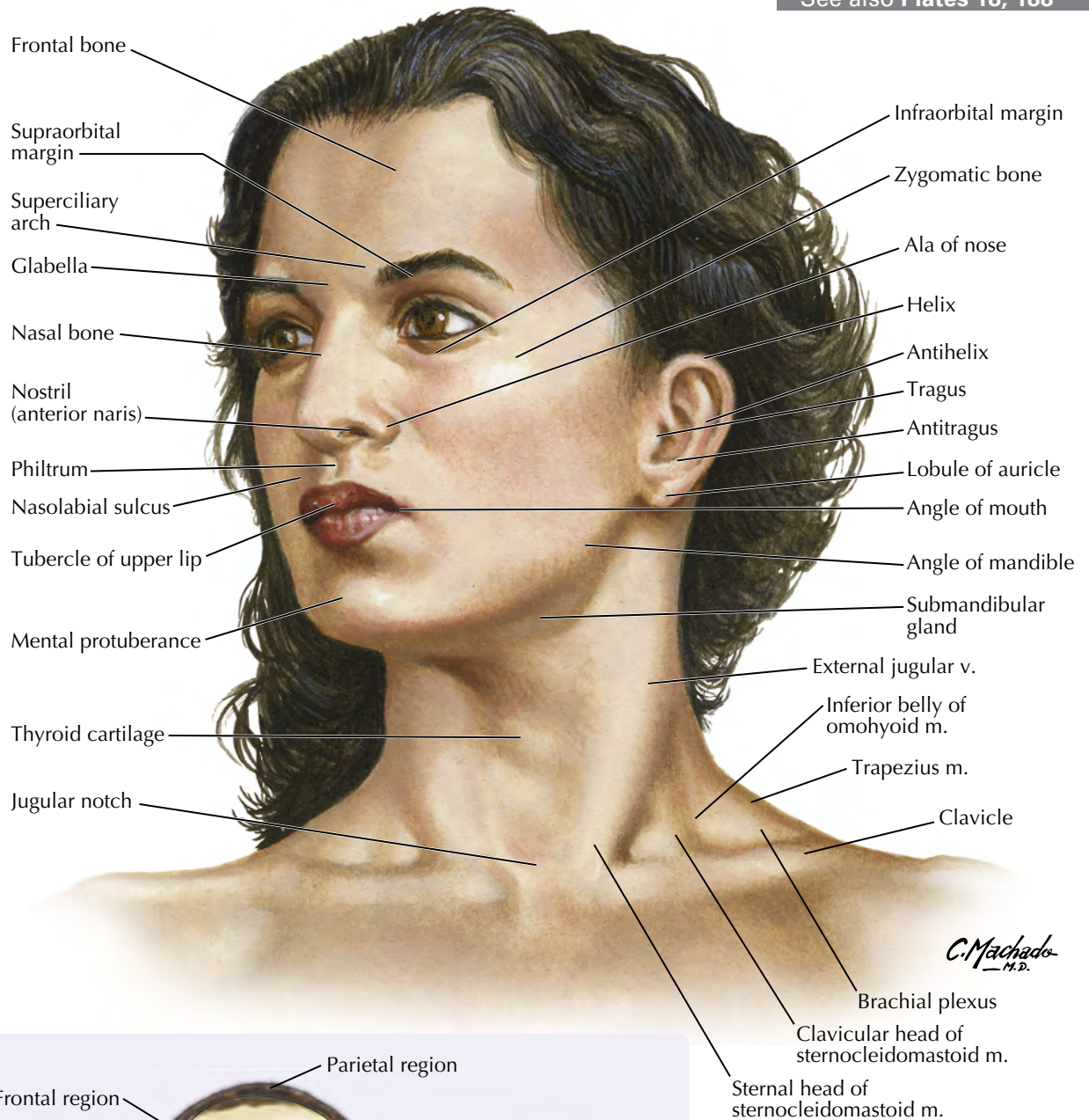


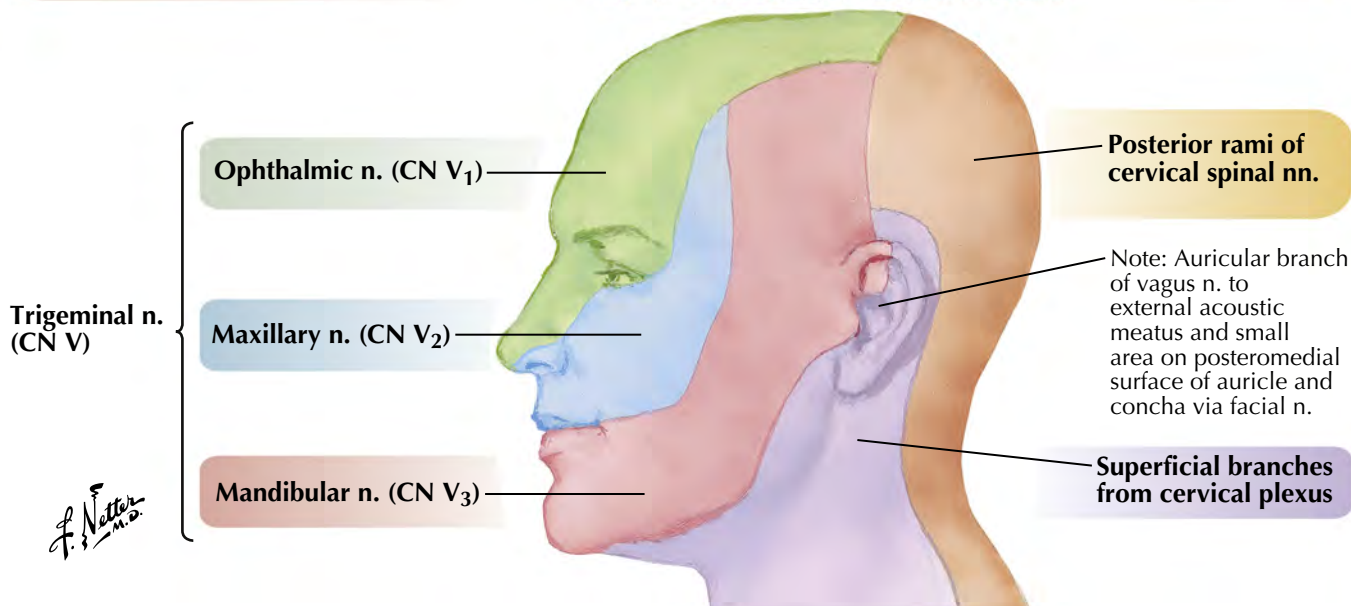
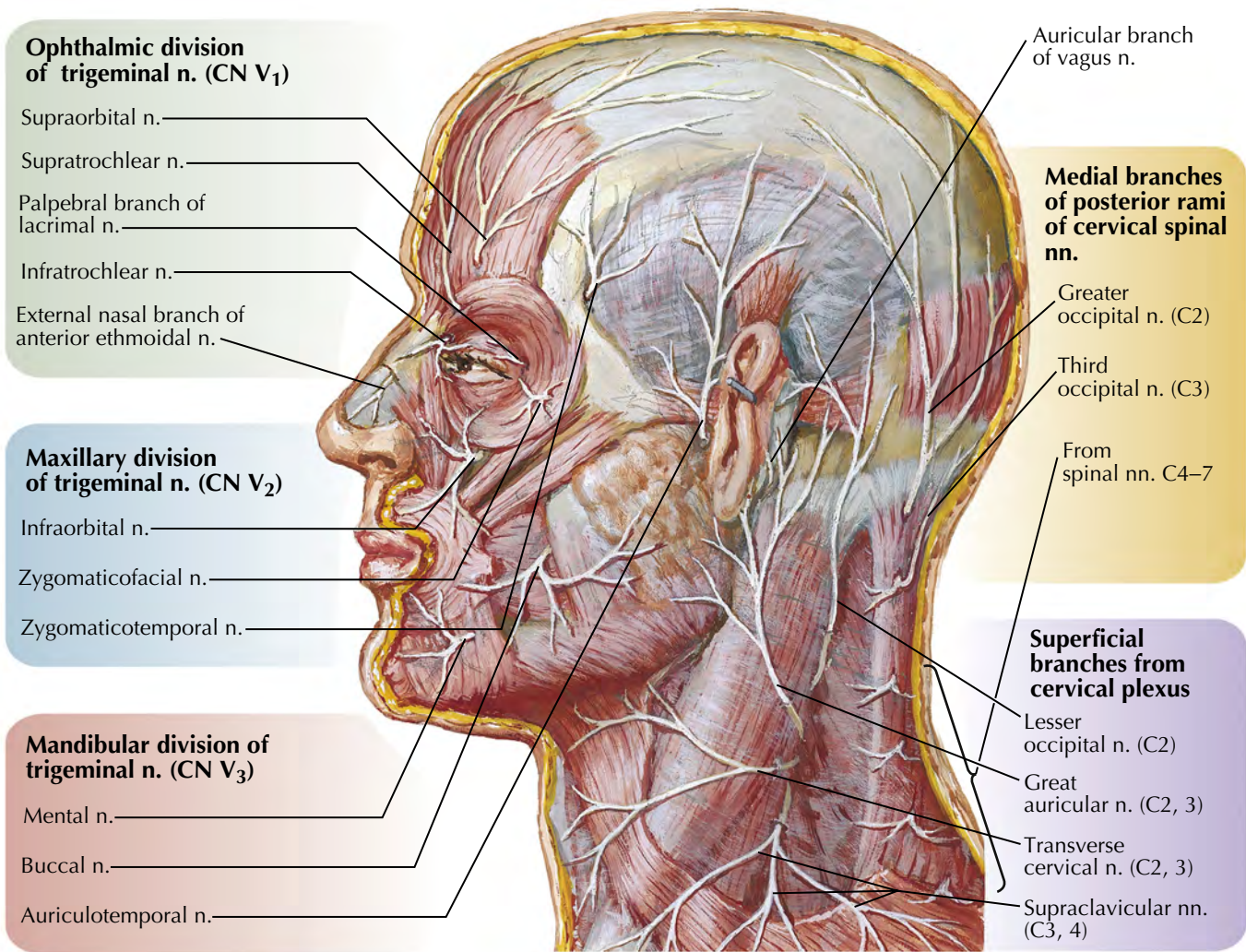
BP 31 Cranial Imaging (MRV and MRA)

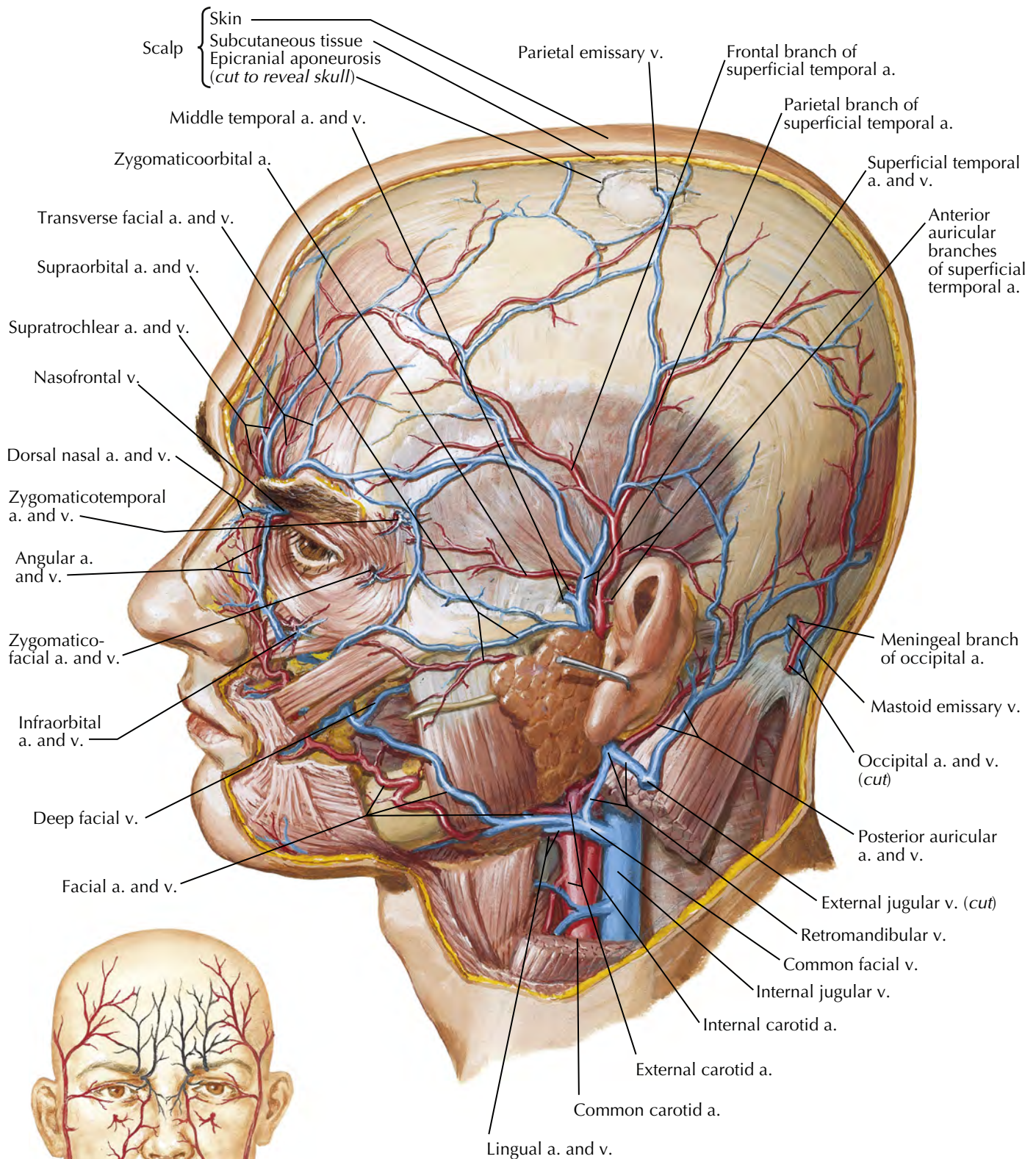


BP 32 Axial and Coronal MRIs of Brain

See also Plates 18, 188





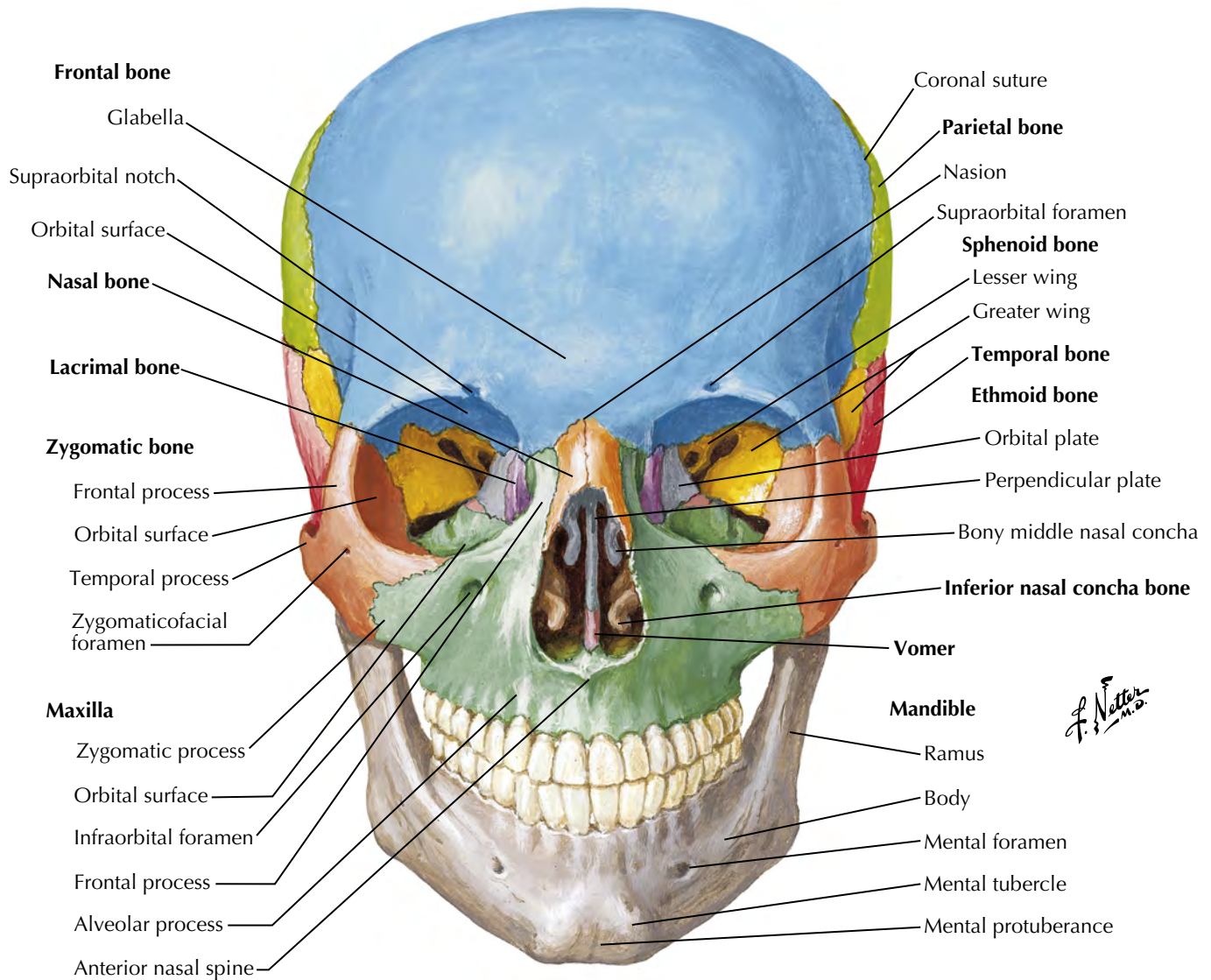


Sources of arterial supply of face

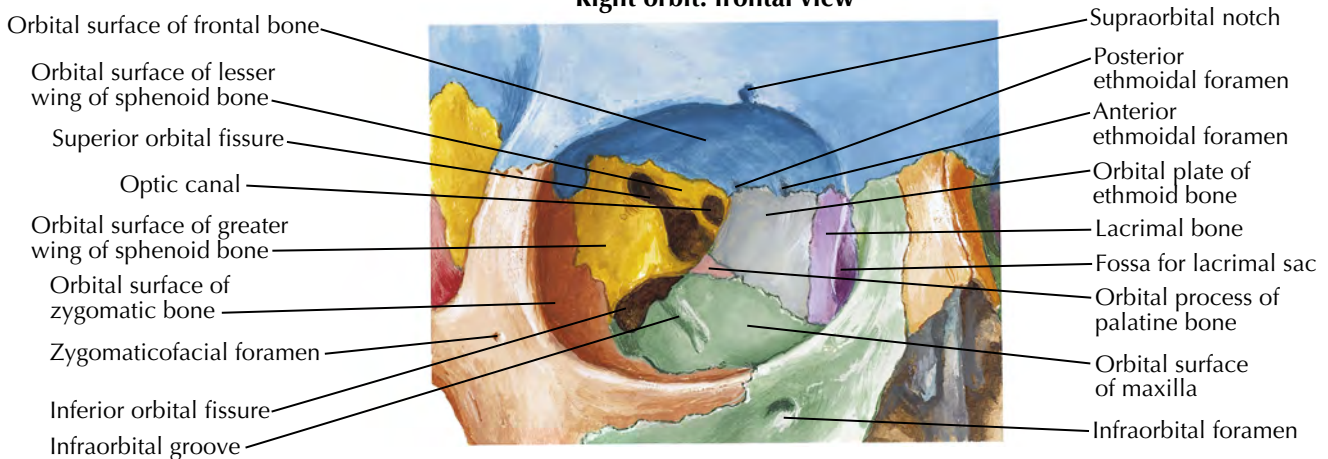
Black: from internal carotid artery (via ophthalmic artery)

Red: from external carotid artery

F. Netter M.D.

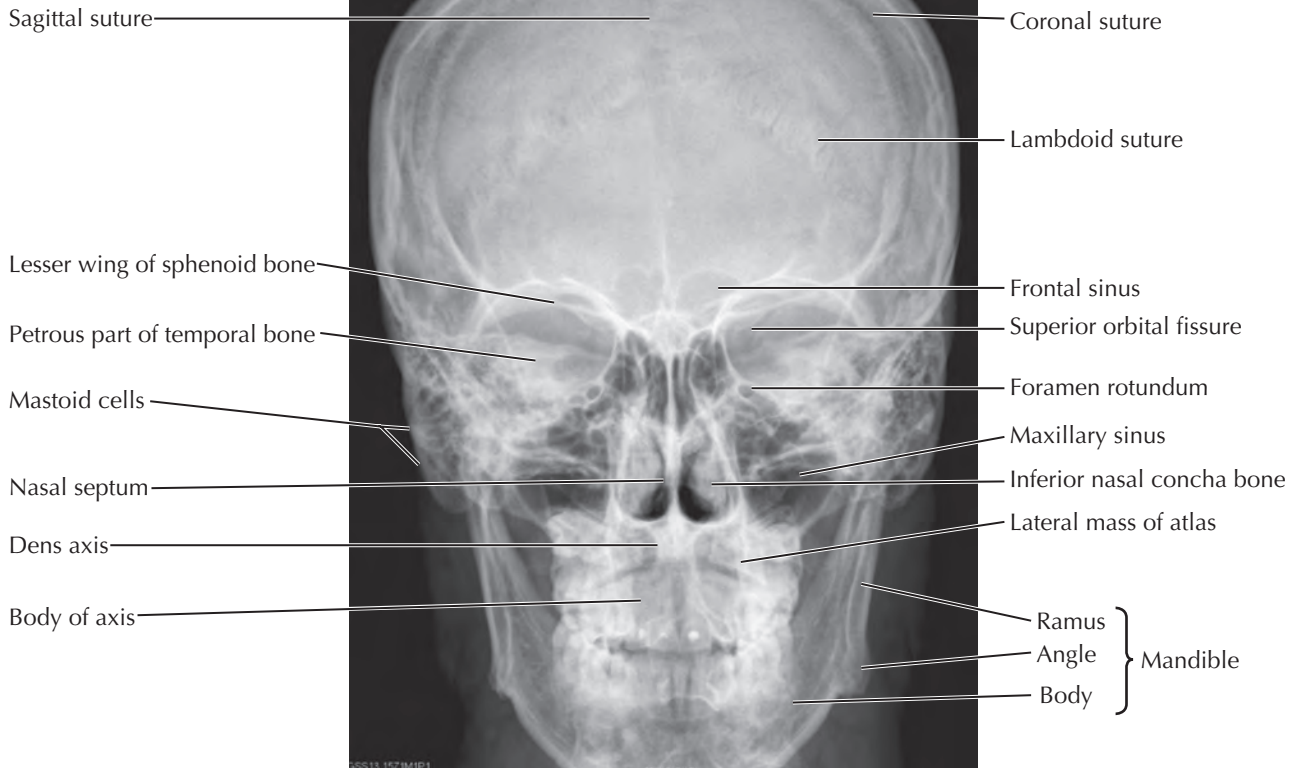


Right orbit: frontal view

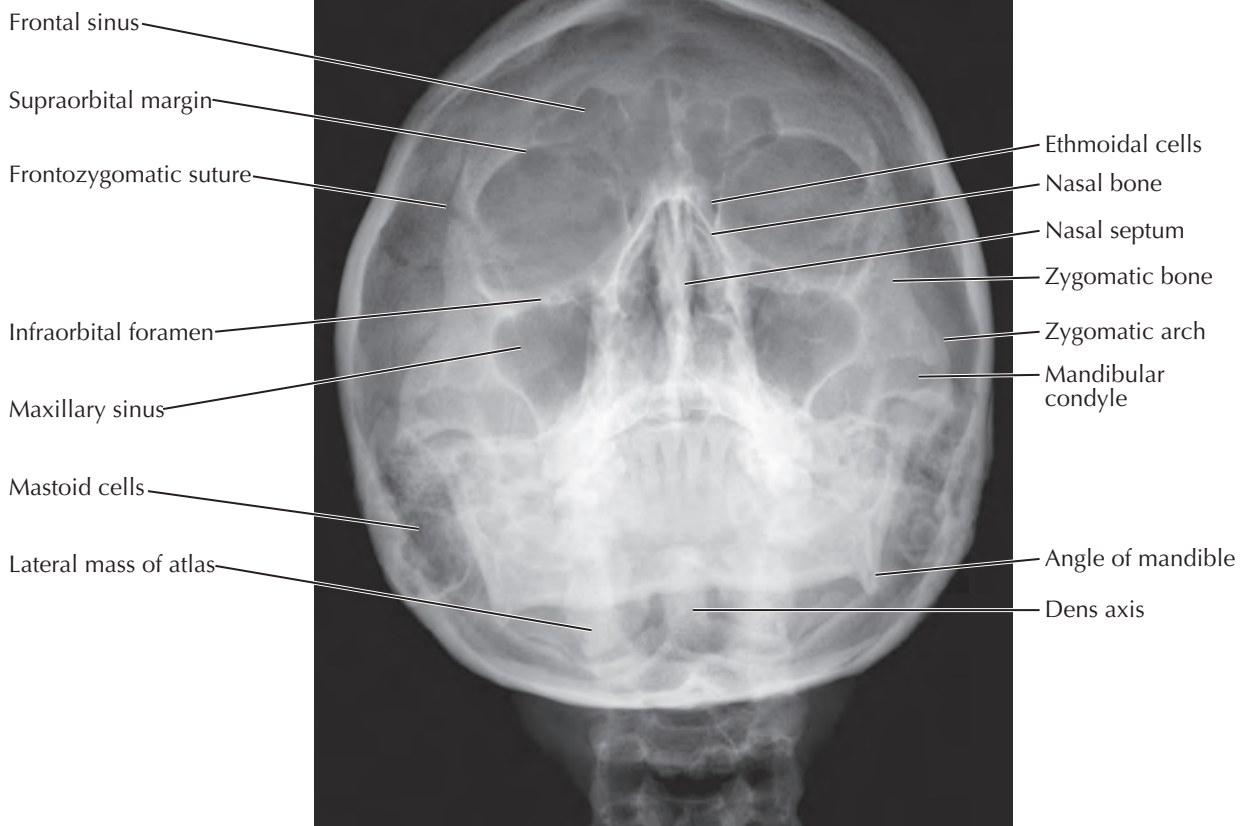


See also Plate 25

Posterior anterior view



Waters' view



Skull: Lateral View

See also Plates 28, 29, 36

